JOURNAL OF
CUTANEOUS IMMUNOLOGY
AND ALLERGY

TYPE Letter to the Editor
PUBLISHED 23 November 2026
DOI 10.3389/jcia.2026.17777

Check for updates

OPEN ACCESS

*CORRESPONDENCE
Shunsuke Takahagi,
takshuns@gmail.com

RECEIVED 05 September 2026
REVISED 11 October 2026
ACCEPTED 12 November 2026
PUBLISHED 23 November 2026

CITATION
Oiwa E, Mizuno H and Takahagi S (2026) Apalutamide-induced Stevens–Johnson syndrome without skin lesions in a Japanese patient.
J. Cutan. Immunol. Allergy 9:17777.
doi: 10.3389/jcia.2026.17777

COPYRIGHT
© 2026 Oiwa, Mizuno and Takahagi. This is an open-access article distributed under the terms of the Creative Commons Attribution License (CC BY). The use, distribution or reproduction in other forums is permitted, provided the original author(s) and the copyright owner(s) are credited and that the original publication in this journal is cited, in accordance with accepted academic practice. No use, distribution or reproduction is permitted which does not comply with these terms.

Apalutamide-induced Stevens–Johnson syndrome without skin lesions in a Japanese patient

Eriko Oiwa, Hayato Mizuno and Shunsuke Takahagi*

Department of Dermatology, JA Hiroshima General Hospital, Hiroshima, Japan

KEYWORDS
androgen receptor inhibitor, apalutamide, prostate cancer, severe cutaneous adverse reaction, Stevens–Johnson syndrome

Dear Editors,

Stevens–Johnson syndrome (SJS) is a severe, potentially life-threatening, mucocutaneous disorder triggered by drugs or infections [1]. It is characterized by extensive mucosal involvement, accompanied by erythematous, blistering, and erosive skin lesions and epidermal detachment affecting ≤10% of the body surface area. In contrast, a rare variant of SJS predominantly affects the mucosa without causing skin lesions and is known as SJS without skin lesions (SWSL), atypical/incomplete SJS, or Fuchs syndrome [2].

Apalutamide is a second-generation androgen receptor inhibitor used for prostate cancer and relates to a high incidence of adverse skin reactions [3]. Although most rashes are mild to moderate, severe cutaneous adverse reactions such as SJS, toxic epidermal necrolysis (TEN), and drug reaction with eosinophilia and systemic symptoms (DRESS) have also been reported [4]. A recent review identified 14 cases of apalutamide-induced SJS/TEN; however, none involved SWSL [4]. Here, we report a case of a Japanese patient with apalutamide-induced SWSL who developed multifocal extensive mucosal erosions but had no accompanying skin lesions.

A 76-year-old Japanese man received androgen deprivation therapy with subcutaneous leuprorelin acetate and oral apalutamide (240 mg/day) for prostate cancer with multiple bone metastases. Concomitant medications included nifedipine, azilsartan, carvedilol, doxazosin, and vonoprazan fumarate. Nine days after starting apalutamide, erosions developed on the lips and oral mucosa. As the mucosal lesions persisted despite discontinuation of apalutamide, he was referred to our department 20 days after starting apalutamide (day 1). The patient presented with low-grade fever, malaise, extensive erosions with hemorrhagic crusts on the lips, and severe oral mucosal erosions (Figure 1A). Erosions were also present in the nasal, genital, and perianal mucocutaneous regions (Figure 1B), and were accompanied by mild conjunctival hyperemia. No skin eruptions were observed.

Laboratory tests showed a white blood cell count of 4,080/μL, an eosinophil count of 510/μL, and a C-reactive protein (CRP) level of 6.9 mg/dL. Although the patient was undergoing maintenance hemodialysis after nephrectomy, no new organ dysfunction was detected. Whole-body computed tomography (CT) showed no infectious foci. Cytomegalovirus pp65 antigenemia was negative, and serologic tests for herpes simplex virus and Epstein–Barr virus were consistent with past infections. Anti-desmoglein 1, anti-desmoglein 3, and anti-BP180 antibodies were negative. Histopathological examination of a lip biopsy specimen revealed subepithelial blister formation with numerous necrotic keratinocytes throughout the entire epithelial thickness (Figures 1C,D).

Based on the clinical course and investigations, the patient was diagnosed with apalutamide-induced SWSL, and prednisolone at 1 mg/kg/day was initiated on day 3. The nasal and anogenital erosions gradually improved, and the eosinophil counts and CRP

10.3389/jcia.2026.17777

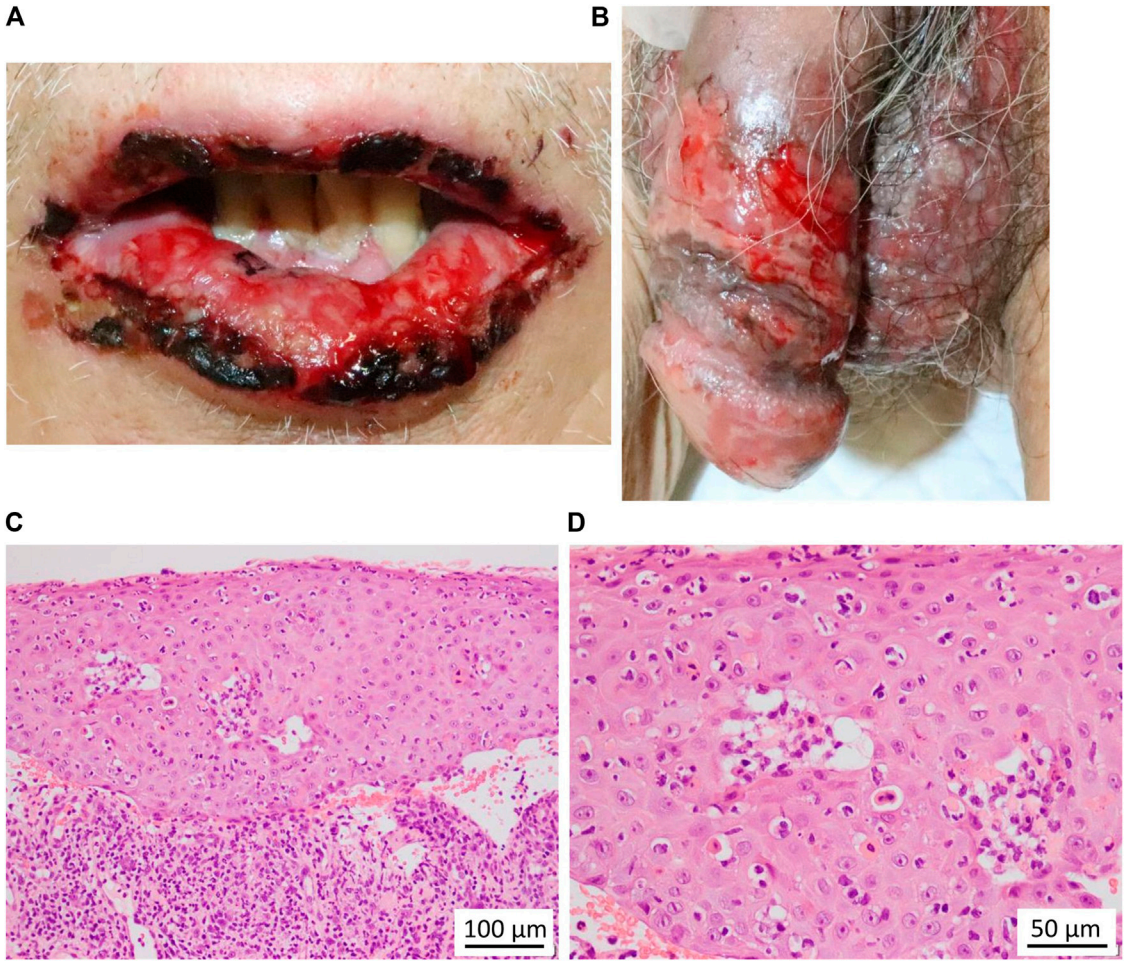

FIGURE 1
Clinical and histopathological findings. **(A,B)** Clinical findings. Extensive erosions with hemorrhagic crusts on the lips **(A)**. Severe erosions involving the genital mucocutaneous region **(B)**. **(C,D)** Histopathological findings in a mucosal biopsy specimen obtained from the lip (hematoxylin and eosin staining). Subepithelial separation is present, accompanied by moderate lymphocytic infiltration, and mild eosinophilic and neutrophilic infiltration into the superficial lamina propria (original magnification, ×200) **(C)**. Numerous necrotic keratinocytes are observed throughout the entire epithelial thickness (original magnification, ×400) **(D)**.

levels decreased. Because the lip and oral erosions persisted, intravenous immunoglobulin (IVIG; 400 mg/kg/day for 5 days) was administered on day 10. The mucosal lesions subsequently re-epithelialized, allowing the prednisolone dose to be tapered and ultimately discontinued on day 44.

Drug-induced lymphocyte stimulation tests were performed for apalutamide, carvedilol, doxazosin, and vonoprazan fumarate, which had been initiated within 1 month before the onset of SWSL. The results were borderline positive for apalutamide but negative for the other three drugs. The Algorithm of Drug Causality for Epidermal Necrolysis (ALDEN) score for apalutamide was 6, indicating a "very probable" causal relationship.

Abbreviations: SJS, Stevens–Johnson syndrome; SWSL, Stevens–Johnson syndrome without skin lesions; TEN, toxic epidermal necrolysis; DRESS, drug reaction with eosinophilia and systemic symptoms; CRP, C-reactive protein; CT, computed tomography; IVIG, intravenous immunoglobulin; ALDEN, The Algorithm of Drug Causality for Epidermal Necrolysis; MP, *Mycoplasma pneumoniae*.

SWSL has been reported mainly in children and young adults in association with *Mycoplasma pneumoniae* (MP) infections, although a small number of drug-induced cases have also been described [2]. Implicated drugs include antibiotics, sulfonamides, nonsteroidal anti-inflammatory drugs, and antiepileptic agents [2]. Because SWSL lacks skin lesions, it should be differentiated from disorders predominantly involving the mucosa, such as infectious stomatitis, fixed drug eruption, autoimmune blistering diseases, and lichen planus. Our patient had widespread mucosal involvement affecting the lips, oral and nasal cavities, and anogenital regions but no skin lesions. Histopathological examination revealed numerous necrotic keratinocytes throughout the epithelium, compatible with SJS. The absence of circulating autoantibodies excluded autoimmune bullous diseases. Together with the temporal relationship between the initiation of apalutamide and the onset of symptoms, the exclusion of infectious diseases, and clinical improvement after apalutamide withdrawal and immunosuppressive therapy, these findings favor the diagnosis of apalutamide-induced SWSL in this case.

Apalutamide is associated with a higher incidence of cutaneous rash than other novel androgen receptor inhibitors. In the SPARTAN and TITAN trials, approximately one-quarter of patients receiving apalutamide developed cutaneous rash, and both rash overall and grade 3 rash occurred more frequently in Japanese patients than in the global trial populations [3]. The reported cases of apalutamide-induced SJS/TEN predominantly involved elderly Asian men, with a median time to onset of 41 days among the 14 reviewed cases [4]. Our patient, an elderly Japanese man, developed symptoms only 9 days after starting apalutamide. Although the onset was earlier than the reported median, it was within the typical 4–28-day interval for drug-induced SJS [1].

Most reported cases of apalutamide-induced SJS/TEN were treated with systemic corticosteroids, IVIG, or both, while a few patients received tumor necrosis factor-α antagonists, cyclosporine, or plasmapheresis [4]. In the present case, prednisolone at 1 mg/kg/day improved some mucosal lesions, whereas the persistent oral lesions prompted the addition of IVIG, resulting in re-epithelialization. If SJS/TEN develops, apalutamide should be permanently discontinued, and alternative treatments for prostate cancer should be considered. It has been proposed that apalutamide's characteristic 2-cyanopyridine moiety reacts with cysteine residues in proteins to form haptens, thereby triggering an immune response that may lead to cutaneous rash [5]. This moiety is absent from other second-generation androgen receptor inhibitors, such as enzalutamide and darolutamide [4]. Based on this structural difference, the cross-reactivity between apalutamide and these agents is considered unlikely [4]; however, clinical evidence supporting the safe use of alternative androgen receptor inhibitors after SJS/TEN remains limited.

A limitation of this study is the lack of microbiological testing for MP. Nevertheless, the absence of preceding respiratory symptoms and CT findings suggestive of MP infections favors a diagnosis of apalutamide-induced SWSL over MP-associated SWSL.

This case demonstrates that apalutamide can cause SWSL. When multifocal mucosal involvement develops during apalutamide treatment, SJS should be considered even in the absence of cutaneous lesions. Careful review of medication history, exclusion of infectious and autoimmune diseases, and mucosal biopsies may facilitate prompt diagnosis and treatment.

Data availability statement

The original contributions presented in the study are included in the article/supplementary material, further inquiries can be directed to the corresponding author.

Ethics statement

Ethical approval was not required for the studies involving humans because this paper reports an individual case. The studies were conducted in accordance with the local legislation and institutional requirements. The participants provided their written informed consent to participate in this study. Written informed consent was obtained from the individual(s) for the publication of any potentially identifiable images or data included in this article.

Author contributions

EO, HM, and ST contributed to data collection and made an interpretation of the results. EO, and ST wrote the manuscript. All authors contributed to the article and approved the submitted version.

Funding

The author(s) declared that financial support was not received for this work and/or its publication.

Conflict of interest

The author(s) declared that this work was conducted in the absence of any commercial or financial relationships that could be construed as a potential conflict of interest.

Generative AI statement

The author(s) declared that generative AI was used in the creation of this manuscript. This manuscript was prepared with the assistance of ChatGPT (OpenAI) to improve linguistic readability. After using the tool, the authors reviewed and edited the content as needed and take full responsibility for the content of the publication.

Any alternative text (alt text) provided alongside figures in this article has been generated by Frontiers with the support of artificial intelligence and reasonable efforts have been made to ensure accuracy, including review by the authors wherever possible. If you identify any issues, please contact us.

References

1. Shah H, Parisi R, Mukherjee E, Phillips EJ, Dodiuk-Gad RP. Update on Stevens-Johnson syndrome and toxic epidermal necrolysis: diagnosis and management. *Am J Clin Dermatol* (2024) 25(6):891–908. doi: 10.1007/s40257-024-00889-6

2. Abuhammad A, Ayyad M, Albandak M, Natsheh M, Attawna SIY. Levofloxacin-induced fuchs syndrome: a rare atypical Stevens-Johnson syndrome variant with a comprehensive literature review. *Case Rep Med* (2025) 2025:9944674. doi: 10.1155/carm/9944674

3. Uemura H, Koroki Y, Iwaki Y, Imanaka K, Kambara T, Lopez-Gitlitz A, et al. Skin rash following administration of apalutamide in Japanese patients with advanced prostate cancer: an integrated analysis of the phase 3 SPARTAN and TITAN studies and a phase 1 open-label study. *BMC Urol* (2020) 20(1):139. doi: 10.1186/s12894-020-00689-0

4. Wang T, Liu S, Yuan R. Apalutamide-induced severe cutaneous adverse reactions in prostate cancer: a comprehensive review of reported cases and clinical strategies. *Front Pharmacol* (2026) 17:1769981. doi: 10.3389/fphar.2026.1769981

5. Ji C, Guha M, Zhu X, Whritenour J, Hemkens M, Tse S, et al. Enzalutamide and apalutamide: *in vitro* chemical reactivity studies and activity in a mouse drug allergy model. *Chem Res Toxicol* (2020) 33(1):211–22. doi: 10.1021/acs.chemrestox.9b00247