JOURNAL OF ABDOMINAL WALL SURGERY
EUROPEAN HERNIA SOCIETY

TYPE Original Research
PUBLISHED 24 November 2026
DOI 10.3389/jaws.2026.17477

Check for updates

OPEN ACCESS

*CORRESPONDENCE
J. P. Rops,
jonas.rops@mmc.nl

RECEIVED 29 July 2026
REVISED 25 October 2026
ACCEPTED 10 November 2026
PUBLISHED 24 November 2026

CITATION
Rops JP, Zwaans WAR, Scheltinga MRM, van Grinsven J, Loos MJA, Roumen RMH and van Eerten PV (2026) Periosteal pubic bone stripping for pubic inguinal pain syndrome in non-athletes: one-year follow-up outcomes.
J. Abdom. Wall Surg. 5:17477.
doi: 10.3389/jaws.2026.17477

COPYRIGHT
© 2026 Rops, Zwaans, Scheltinga, van Grinsven, Loos, Roumen and van Eerten. This is an open-access article distributed under the terms of the Creative Commons Attribution License (CC BY). The use, distribution or reproduction in other forums is permitted, provided the original author(s) and the copyright owner(s) are credited and that the original publication in this journal is cited, in accordance with accepted academic practice. No use, distribution or reproduction is permitted which does not comply with these terms.

Periosteal pubic bone stripping for pubic inguinal pain syndrome in non-athletes: one-year follow-up outcomes

J. P. Rops [1,2]*, W. A. R. Zwaans [1,2,3], M. R. M. Scheltinga[1,2], J. van Grinsven[1,2], M. J. A. Loos [1,2], R. M. H. Roumen [1,2] and P. V. van Eerten[1,2]

[1]Department of Surgery, Máxima Medical Center, Veldhoven, Netherlands, [2]SolviMáx, Center of Expertise for Complex Groin and Abdominal Wall Pathology, Eindhoven, Netherlands, [3]NUTRIM School of Nutrition and Translational Research in Metabolism, Maastricht University, Maastricht, Netherlands

Purpose: Pubic inguinal pain syndrome (PIPS) in non-athletes with a history of inguinal hernia repair is hypothesized to result from a persistent postoperative nociceptive response involving the pubic bone, including its periosteum and attachments. It may emerge as a distinct entity within chronic postoperative inguinal pain (CPIP). This study evaluates outcomes of partial resection of the anterior pubic periosteum with release of the adjacent attachments in refractory cases.

Methods: Consecutive patients with chronic (>6 months) PIPS refractory to conservative treatment, operated at our tertiary referral center between 2015 and 2020, were analyzed. Data were collected prospectively before surgery and at 4–6 weeks, 3, 6, 9 and 12 months using the Copenhagen Hip and Groin Outcome Score (HAGOS) and Visual Analogue Scale (VAS), and analyzed using linear mixed models.

Results: Of 81 operated patients, 60 were analyzed (46 male, mean age 50 years, mean symptom duration 4.1 years). HAGOS improved significantly in five of six domains, but only 21%–48% reached good function (≥75 points) at 12 months. Estimated mean VASmin decreased from 4.7 to 2.9 and VASmax from 7.7 to 5.7. A minimal clinically important difference (MCID) in pain was achieved by 59% for resting and 45% for activity-related pain. Complications occurred in 27% (Clavien-Dindo I–III).

Conclusion: Removal of the pubic periosteum and release of adjacent tissues may improve hip and groin function and reduce pain in a subset of non-athlete PIPS patients with a history of inguinal hernia repair. However, it should be considered a last-resort option, and thorough preoperative counselling is warranted.

KEYWORDS
chronic postoperative inguinal pain (CPIP), inguinal herniorrhaphy, pain managements, periosteum, pubic bone

Introduction

Campanelli first described pubalgia, also termed Pubic Inguinal Pain Syndrome (PIPS) or periostitis pubis, in 2010 [1]. It is characterized by chronic groin pain localized to the pubic bone [1, 2]. It is often seen in athletes or individuals who are physically active due to repetitive muscle traction causing inflammation at the periosteum–bone interface [1, 2]. However, pubalgia may also affect non-athletes, arising spontaneously or commonly

following abdominal, urologic, or gynecologic procedures [3, 4]. It is hypothesized to result from a persistent postoperative nociceptive response involving the pubic periosteum and its ligamentous and tendinous attachments, reflecting a potentially distinct pathophysiological mechanism. Importantly, it differs from other forms of chronic postoperative inguinal pain, which can be mesh-related or caused by nerve injury [5–7].

Patients typically report localized unilateral pain at the pubic bone, which may irradiate towards the pubic tubercle and ends at the adductor muscles insertion of the inner thigh [1, 2]. Trunk movements during sitting or hip flexion commonly provoke these symptoms. This pain often worsens with movement, progressively limiting range of motion and significantly impairing quality of life [1, 2].

Following inguinal hernia repair, pubalgia may emerge as a distinct entity within the (CPIP) spectrum [6–8]. In most cases, this presents as a mixed pain picture in which neuropathic and nociceptive, components coexist and can rarely be distinguished. As a first step, conservative treatment options are initiated, including analgesics, physical therapy, local infiltration with local anesthetics (e.g., lidocaine or bupivacaine), local infiltrations with corticosteroids, or pulsed radiofrequency (PRF) of the inguinal nerves. If these treatments fail, invasive surgical interventions such as ilioinguinal neurectomy or mesh removal may be considered [7, 9]. When neuropathic and mesh-related components have been addressed (or excluded), the underlying state of the pubic periosteum may become the dominant source of pain, often described by patients as a shift in pain character towards solely the pubic bone [1, 2, 6]. However, despite this stepwise approach with both non-surgical and surgical treatment options, a subset of patients continues to experience pain of the pubic bone refractory to all preceding treatments.

Partial resection of the superficial anterior pubic periosteum, combined with release of the adjacent inguinal (Poupart's) ligament attachment and a limited detachment of the lateral rectus abdominis insertion from the pubic crest, has been proposed as a treatment option for refractory cases. However, current evidence regarding its outcomes remains limited [10, 11]. The present study describes the functional and pain outcomes, as well as the complications, of this surgical intervention in (non-athlete) CPIP patients with PIPS following inguinal hernia repair and persistent pubalgia despite extensive conservative management and previous surgical treatment.

Materials and methods

Setting and ethics

This study was conducted at SolviMáx, a subdivision of the surgical department of Máxima Medical Centre in Eindhoven/Veldhoven (the Netherlands), serving as an (inter)national tertiary referral centre for the management of chronic abdominal wall and inguinal pain syndromes. The study protocol was approved by the local medical ethics committee. At intake, all patients were routinely informed that their clinical data could be used for research purposes and were given the opportunity to decline. Only patients who consented to research use of their data were included in this study.

TABLE 1 Clinical presentation, physical examination, and imaging characteristics of patients with pubic inguinal pain syndrome.

Clinical findings
Pain is experienced at the lateral area of the pubic bone (including pubic tubercle)
Pain may radiate towards adductor muscles
Pain is aggravated by exercise (in particular hip flexion or trunk movement)
Findings by physical examination
Absence of pain along the inguinal canal
Pain provoked by exerting local pressure on the ipsilateral pubic tubercle
Sensory disturbances (including hyperesthesia) may be present
Findings on additional imaging
MRI*: may reveal (mild) periosteal edema
MRI*: ruled out other diagnoses (in particular osteomyelitis of the pubic bone)

*MRI, magnetic resonance imaging.

Patients

The study population included consecutive non-athlete patients with chronic (>6 months) PIPS between 2015 and 2020, all with a history of inguinal hernia repair. All had undergone a mix of conservative treatment including physical therapy, analgesics, and repeated infiltration therapy with local anesthetics (with or without corticosteroids) without sustained relief. In addition, a subset of patients had previously undergone surgical interventions aimed at pain relief, including ilioinguinal neurectomy or mesh removal, none of which had resulted in adequate or sustained pain reduction. Patients with bilateral groin pain, infection, inoperability, or insufficient Dutch language proficiency were excluded.

Diagnostics

PIPS was diagnosed clinically, on the basis of medical history and physical examination. Physical examination included standardized assessment of bone tenderness by direct palpation of the anterior pubic bone. Pain typically originated at the pubic tubercle, at the insertion of the inguinal (Poupart's) ligament, sometimes including the lateral part of the rectus abdominis insertion on the pubic crest, and extended inferomedially along the anterior surface of the pubic bone, up to the origin of the adductor longus tendon without crossing the pubic symphysis.

Additionally, testing for hyperalgesia ("Pinch test") was performed to evaluate cutaneous hypersensitivity and pain provocation in the inguinal skin region. Involvement of the ilioinguinal nerve was assessed at the level of the anterior superior iliac spine (ASIS), and the genitofemoral nerve and funiculus were evaluated for diffuse pain in their respective sensory distributions. Recurrent inguinal or femoral hernias were systematically excluded by physical examination and ultrasonography, either at our institution or at other institutions, depending on the previous diagnostic workup.

Magnetic Resonance Imaging (MRI) was performed on patients to exclude alternative pathology (Table 1).

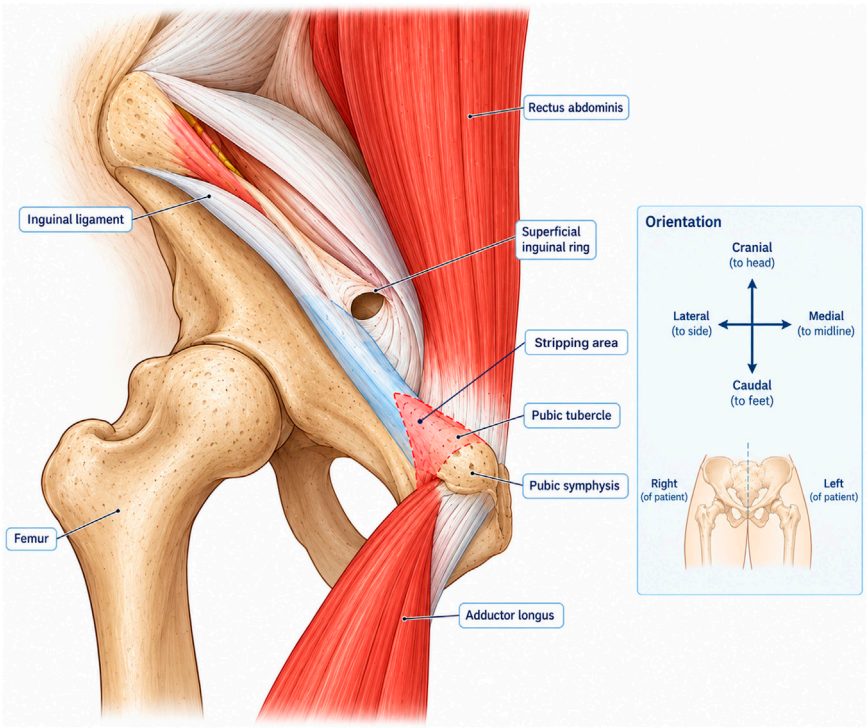

FIGURE 1
Schematic anterior view of the right groin showing the surgical approach in Pubic Inguinal Pain Syndrome (PIPS). The red dashed area marks the stripping area. The periosteum of the anterior pubic surface is stripped infero-medially up to the origin of the adductor longus tendon, which is left intact. The soft tissue at the pubic tubercle is detached: the medial insertion of the inguinal ligament and a small part of the lateral rectus abdominis insertion. Orientation: cranial (top), caudal (bottom), lateral (left), medial (right).

Surgical technique

Under general anesthesia, a 6–8 cm incision was made in the groin fold. Soft tissue at the pubic tubercle, including the insertion of the medial fibers of the inguinal ligament and a small portion of the lateral rectus abdominis insertion on the pubic crest, was detached and removed. The periosteum of the anterior surface of the pubic bone was then stripped infero-medially to the origin of the adductor longus tendon, which was left intact. The pubic symphysis was not exposed. Hemostasis was carefully performed, and a depot of bupivacaine was administered along the anterior surface of the pubic bone. The wound was closed in layers. A schematic illustration and representative intraoperative images demonstrating the surgical field before and after periosteal stripping are shown in Figures 1–3.

Mean operative time was approximately 30 min. Patients received routine analgesia (paracetamol, NSAIDs, and opioids on indication) and were discharged within 24 h. The inguinal canal was not opened and no histological evaluation was performed.

Follow-up

Postoperative follow-up was conducted at 4–6 weeks and at 3, 6, 9, and 12 months. Due to the COVID-19 pandemic, a proportion of follow-up visits were conducted via telephone and digital questionnaires, and response rates were reduced at certain time points. Not all patients completed every follow-up assessment. The number of patients with available data at each time point is reported in the figures.

Outcome measures

The primary outcome focused on hip and groin function and quality of life. This was evaluated using the Copenhagen Hip and Groin Outcome Score (HAGOS), a validated patient-reported outcome measure comprising six subscales each scored from 0 to 100. A score of ≥75 points was used as an arbitrary threshold for good function.

The secondary outcomes were pain intensity assessed using the Visual Analogue Scale (VAS) from 0 (no pain) to 10 (worst imaginable pain), and physical findings on examination. VAS was recorded for pain at rest (VASmin) and during activity (VASmax). Clinically important change was defined as a reduction of ≥2 points or ≥30% from the pre-operative score, corresponding to the minimal clinically important difference (MCID), and substantial improvement as a reduction of ≥50% [12, 13]. Pain severity was categorised as mild (0–3), moderate (4–6) or severe (7–10). Bone tenderness over the pubic bone and cutaneous hypersensitivity on the pinch test were recorded as dichotomous outcome measures. Complications were recorded and graded according to the Clavien-Dindo classification.

Statistical analysis

Changes in HAGOS and VAS scores over time were analyzed using linear mixed models (LMM) with a random intercept per patient and time point as a categorical fixed effect. This approach accounts for repeated measurements and uses all available

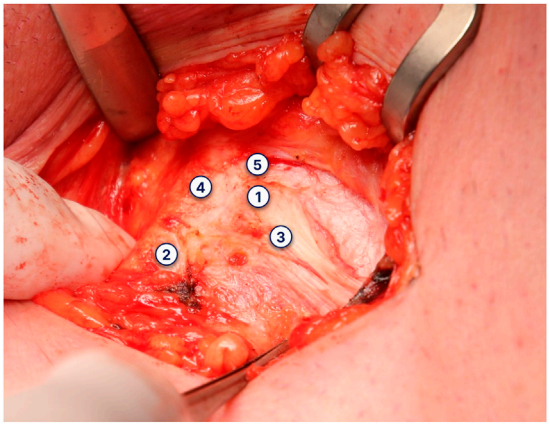

① Pubic tubercle
② Adductor longus muscle
③ Inguinal ligament (Poupart's ligament)
④ Pubic bone
⑤ Lateral part of the rectus abdominis

FIGURE 2
Intra-operative view of the left groin in a patient with Pubic Inguinal Pain Syndrome (PIPS), before periosteal stripping. 1 = pubic tubercle; 2 = adductor longus muscle; 3 = inguinal (Poupart's) ligament; 4 = pubic bone; 5 = lateral part of the rectus abdominis. Orientation: medial (left), lateral (right), cranial (top), caudal (bottom). Written informed consent for publication of this image was obtained from the patient.

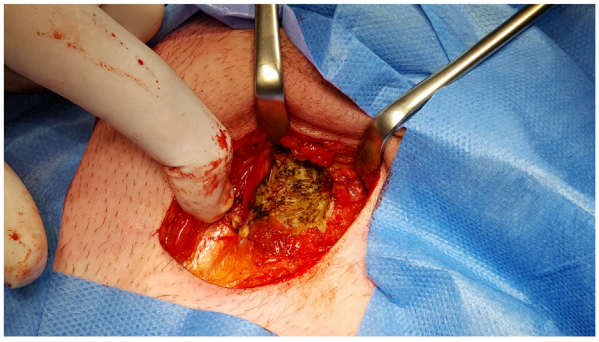

FIGURE 3
Intra-operative view of the left groin in a patient with Pubic Inguinal Pain Syndrome (PIPS), after detachment of the medial fibres of the inguinal ligament and part of the lateral rectus abdominis insertion at the pubic tubercle, and stripping of the anterior pubic periosteum inferomedially to the origin of the adductor longus, which was left intact. Orientation: medial (left), lateral (right), cranial (top), caudal (bottom). Written informed consent for publication of this image was obtained from the patient.

observations of each patient, under the assumption that missing data are missing at random. All analyses were performed within the same cohort of operated patients. The overall effect of time was assessed with a Wald test. Results are presented as estimated marginal means (EMM) and mean changes from the pre-operative score, each with 95% confidence intervals (CI). Responder rates and pain severity categories were calculated for patients with data available both pre-operatively and at 12 months. Paired categorical outcomes were compared across time points using the McNemar test. Descriptive statistics for continuous variables are presented as means with standard deviations (SD) or medians with interquartile range (IQR) where appropriate. Categorical variables are presented as counts and percentages (%). A p-value of less than 0.05 was considered statistically significant. All analyses were performed using SPSS and RStudio.

Results

Patients and baseline characteristics

Between 2015 and 2020, 110 patients were referred to our centre with suspected pubalgia and a history of inguinal hernia repair. Of these, 29 patients were treated conservatively or did not have pubalgia and were therefore not eligible. The remaining 81 patients underwent periosteal stripping with detachment of the medial fibres of the inguinal (Poupart's) ligament and a small portion of the lateral rectus abdominis attachment. Nine patients were excluded because of bilateral pathology (n = 8) or inability to complete the questionnaires (n = 1), leaving 72 patients eligible for study. As preoperative data in 12 patients were insufficient, a total of 60 patients were studied (Figure 4).

The mean age at the time of surgery was 50 years, with a sex distribution of 46 males and 14 females. Median symptom duration was 4 years. Symptoms were localized to the right side of the pubic bone in 33 patients (55.0%) and the left side in 27 patients (45.0%).

All patients were diagnosed with PIPS and had a previous mesh-based inguinal hernia repair. The index repair was a Lichtenstein repair in 36 patients (60.0%), a plug repair in 1 (1.7%), a totally extraperitoneal (TEP) repair in 18 (30.0%), a transabdominal preperitoneal (TAPP) repair in 1 (1.7%), a transrectus sheath preperitoneal (TREPP) repair in 2 (3.3%), a transinguinal preperitoneal (TIPP) repair in 1 (1.7%), and a Stoppa repair in 1 (1.7%). The mesh was positioned anteriorly in 37 patients (61.7%) and in the preperitoneal space in 23 patients (38.3%). No patients had undergone a tissue repair. Information on the mesh fixation technique, including fixation at or near the pubic tubercle, was not consistently available in the referral records (Table 2).

A clinically evident inguinal hernia prior to the index repair, confirmed by a palpable bulge, was documented in 26 patients (43.3%). In 13 patients (21.7%), the diagnosis was based solely on ultrasonographic evidence, without documentation of a palpable bulge. For the remaining 21 patients (35.0%), information regarding the original indication for surgery and the preoperative clinical presentation could not be retrieved from the available medical records, most of which dated back several years.

Prior to surgical intervention, all patients received at least one course of a minimum of three local injections with lidocaine, with or without corticosteroids, at our centre, irrespective of previous treatments elsewhere. In addition, at least 35 patients (58.3%) had undergone neurectomy (e.g., of the ilioinguinal nerve), 18 (30.0%) a mesh removal, and a considerable proportion had received pulsed radiofrequency (PRF) treatment. This underlines that, prior to periosteal stripping, patients received extensive conservative treatment, as well as interventions targeting other potential pain mechanisms. The reported numbers are based on verified documentation only. The actual number of patients who underwent these interventions is possibly higher, but this could not

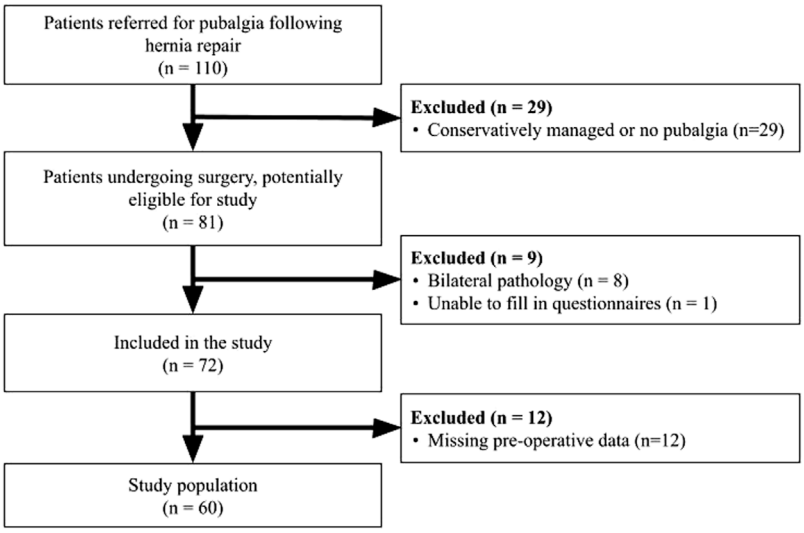

FIGURE 4
Flowchart of patient selection and inclusion. Between 2015 and 2020, 110 patients with suspected pubalgia after inguinal hernia repair were referred to our centre. Following eligibility assessment and exclusion of patients with bilateral pathology, inability to complete questionnaires, or insufficient preoperative data, 60 patients were included in the final analysis.

be determined with certainty because a substantial proportion of the cohort had been referred from external centers, resulting in incomplete medical records and missing information regarding previous treatments.

As part of the preoperative workup, all patients underwent MRI prior to surgery. A cleft sign was identified in one case (1.7%), indicative of pubic osteitis, while sclerosis surrounding the pubic bone was observed in a second case (1.7%), suggestive for previous periostitis. Additionally, imaging findings consistent with enthesitis or enthesopathy were present in two cases (3.3%). Notably, no classic pubic bone marrow edema was identified in any of the patients.

TABLE 2 Baseline characteristics patients population (n = 60).

Variable	Value
Sex	46 male (77%)/14 female (23%)
Side	33 rights (55%)/27 left (45%)
Age	50 Years (IQR* 14.9)
Duration of symptoms	4.1 Years (IQR* 3.5)
Posterior index repair	37 patients (62%)
Anterior index repair	23 patients (38%)

*IQR, interquartile range.

Primary outcome

Functional recovery, assessed using the HAGOS across six domains: Symptoms, Pain, Activities of Daily Living (ADL), Sport and Recreation (Sport/Recr.), Participation, and Quality of Life (QoL) showed statistically significant improvement over time in five of the six domains.

Between the pre-operative assessment and 12 months, estimated mean scores improved by 16.4 points for Symptoms, 18.3 points for Pain, 22.4 points for ADL, 22.2 points for Sport/Recr. , and 22.1 points for QoL.

For the Participation domain, the overall effect of time was not statistically significant ($p = 0.128$), although the estimated mean score at 12 months was 15.5 points higher compared to pre-operative HAGOS. This indicates a less consistent pattern of improvement across time points in this domain (Table 3).

The proportion of patients with scores ≥75 points, considered indicative of normal functioning, increased in all domains. Pre-operatively, scores ≥75 were recorded in 5%, 2%, 7%, 7%, 7% and 0% of patients for Symptoms, Pain, ADL, Sport/Recr., Participation and QoL, respectively (n = 60). At 12 months, these proportions were 36%, 36%, 48%, 33%, 27% and 21%, respectively (n = 33). Nevertheless, the majority of patients did not reach normal functioning in any domain at 12 months (Figure 5).

Secondary outcome

Both resting pain (VASmin) and activity-related pain (VASmax) improved significantly over the follow-up period (overall effect of time, both $p < 0.001$). The estimated mean VASmin decreased from 4.7 pre-operatively to 2.9 at 12 months, a mean reduction of 1.8 points (95% CI 1.1–2.6), and the estimated mean VASmax decreased from 7.7 to 5.7, a mean reduction of 2.0 points (95% CI 1.1–2.9) (Table 4.)

Among patients with VAS scores available both pre-operatively and at 12 months (n = 33), a clinically important reduction in pain at the individual level (MCID) was observed in 58.6% for resting pain and 44.8% for activity-related pain. A substantial reduction of ≥50% was achieved by 44.8% and 27.6% of patients, respectively.

Pain remained unchanged in 6.9% of patients at rest and 24.1% during activity.

TABLE 3 Linear mixed model of changes in HAGOS outcome measures over 12 Months.

Subscale	Pre-operative EMM* (95% CI)	12 months EMM* (95% CI)	Difference (95% CI)	p-value†
Symptoms	45.6 (39.8–51.4)	61.9 (55.6–68.3)	16.4 (9.4–23.3)	<0.001**
Pain	40.9 (34.7–47.2)	59.3 (52.4–66.1)	18.3 (10.7–25.9)	<0.001**
ADL	37.9 (30.4–45.3)	60.3 (52.1–68.4)	22.4 (13.3–31.5)	<0.001**
Sport/Recr	31.6 (24.0–39.3)	53.8 (45.4–62.2	22.2 (12.8–31.5)	<0.001**
Participation	21.9 (13.1–30.6)	37.4 (27.7–47.1)	15.5 (4.3–26.7)	0.128
QoL	21.7 (14.6–28.8)	43.9 (36.0–51.7)	22.1 (12.9–31.4)	<0.001**

Linear mixed model with a random intercept per patient and time point as a categorical fixed effect (pre-operative, 4–6 weeks, 3, 6, 9 and 12 months), using all available observations. Scores range from 0 to 100; higher scores indicate better function. *EMM, estimated marginal mean: model-based mean derived from the linear mixed model. †Overall effect of time across all six time points (Wald test). CI, confidence interval; ADL, activities of daily living; Sport/Recr., sport and recreation function; QoL, quality of life; $p < 0.005$**.

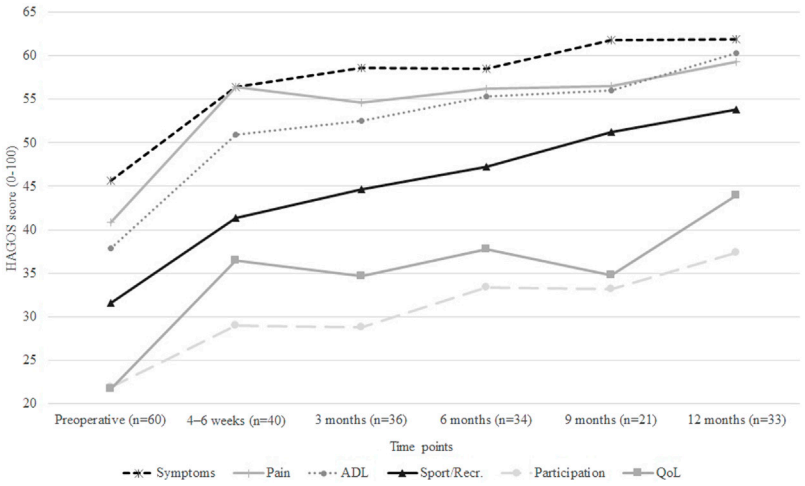

FIGURE 5
Hip and Groin Outcome Score (HAGOS) subscale scores over 12 months of follow-up in patients with Pubic Inguinal Pain Syndrome (PIPS), across six domains: Symptoms, Pain, Activities of Daily Living (ADL), Sport and Recreation Function (Sport/Recr.), Participation, and Quality of Life (QoL). Points represent estimated marginal means (EMM) derived from a linear mixed model with a random intercept per patient, using all available observations. Scores range from 0 to 100, with higher scores indicating better function. The number of patients with available data at each time point is shown below the x-axis.

TABLE 4 Linear mixed model of changes in VAS pain scores over 12 Months.

Measure	Pre-operative EMM* (95% CI)	12 months EMM* (95% CI)	Difference (95% CI)	p-value†
VAS min	4.7 (4.2–5.3)	2.9 (2.2–3.5)	−1.8 (−2.6; −1.1)	<0.001**
VAS max	7.7 (7.0–8.3)	5.7 (4.9–6.5)	−2.0 (−2.9; −1.1)	<0.001**

Linear mixed model with a random intercept per patient and time point as a categorical fixed effect (pre-operative, 4–6 weeks, 3, 6, 9 and 12 months), using all available observations. VAS, scores range from 0 to 10; lower scores indicate less pain. Negative changes indicate a reduction in pain. *EMM, estimated marginal mean: model-based mean derived from the linear mixed model; unlike observed means, EMMs, account for missing follow-up data by using all available measurements of each patient.†Overall effect of time across all six time points (Wald test). CI, confidence interval; VAS, visual analogue scale; VAS, min, resting pain; VAS, max, activity-related pain. $p < 0.005$**.

The proportion of patients with mild resting pain (VASmin ≤3) increased from 31.0% pre-operatively to 58.6% at 12 months, whereas severe resting pain (VASmin ≥7) decreased slightly from 10.3% to 6.9%.

For activity-related pain, the proportion of patients with mild pain (VASmax ≤3) increased from 3.4% to 24.1%, and severe pain (VASmax ≥7) decreased from 82.8% to 44.8%. Nevertheless, nearly half of patients continued to report severe pain during activity at 12 months (Figure 6).

The prevalence of pubalgia decreased markedly over 12 months' time, from 100% at baseline to 56% at 12 months, representing a statistically significant reduction ($p = 0.023$). At 12 months, nearly half of all patients were free of pubalgia.

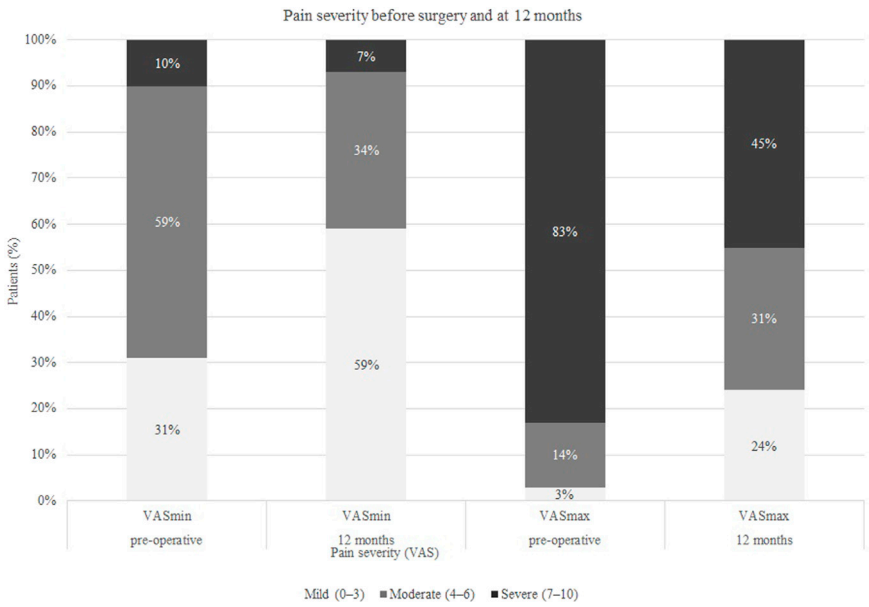

FIGURE 6
Distribution of pain severity pre-operatively and at 12 months after surgery in patients with Pubic Inguinal Pain Syndrome (PIPS). Pain was measured on a Visual Analogue Scale (VAS) from 0 (no pain) to 10 (worst imaginable pain). VASmin, resting pain, VASmax, activity-related pain. Pain was categorised as mild (0–3), moderate (4–6) or severe (7–10). Bars show the percentage of patients in each category. Only patients with VAS scores available at both time points were included.

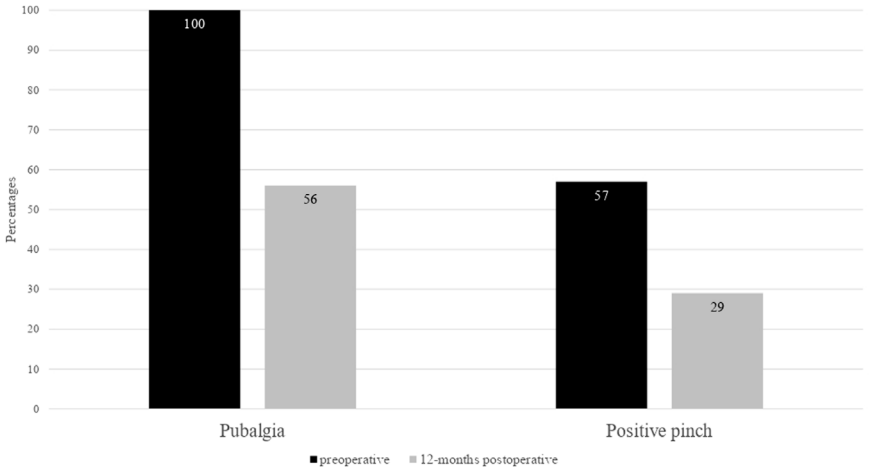

FIGURE 7
Clinical symptoms before and after periosteal pubic bone stripping in patients with Pubic Inguinal Pain Syndrome (PIPS), including pubic bone pain (pubalgia) and pinch test positivity. Pubalgia refers to pain elicited by palpation of the pubic bone (os pubis). The pinch test was performed to evaluate cutaneous hypersensitivity and pain provocation (hyperalgesia) in the inguinal skin region.

The proportion of patients with a positive pinch test decreased from 57.1% at baseline to 47.6% at 6 months and 29.4% at 12 months. However, these reductions did not reach statistical significance at either time point ($p = 0.480$ and $p = 0.074$, respectively) (Figure 7).

Postoperative complications

Out of the 60 operated patients, 44 (73%) experienced no complications. Two patients developed a postoperative hematoma (3.3%) requiring no intervention, and one patient developed a postoperative bleeding (1.7%) managed conservatively, these were classified as Clavien-Dindo grade I. Seven patients developed superficial wound infections (11.7%), and four patients developed an infected hematoma (6.7%) both managed with antibiotic therapy, corresponding to Clavien-Dindo grade II. Finally, one patient developed a recurrent inguinal hernia requiring reoperation, and one patient developed an ischemic orchitis necessitating surgical intervention; both were classified as Clavien-Dindo grade IIIb. No

complications of grade IV or V were observed. No instability of the pubic symphysis was observed.

Discussion

This study evaluated the outcomes of periosteal stripping with detachment of the Poupart ligament and a small portion of the lateral rectus abdominis muscle attachment in 60 patients with Pubic Inguinal Pain Syndrome (PIPS) and a history of inguinal hernia repair. The HAGOS improved significantly in five of six domains, with the largest mean gains in ADL, Sport/Recr. and QoL (approximately 22 out of 100 points each). Nevertheless, at 12 months the proportion of patients reaching good function (≥75 points) ranged from only 21% (QoL) to 48% (ADL). Pain improved in some patients, estimated mean resting pain decreased from 4.7 to 2.9 and activity-related pain from 7.7 to 5.7. A MCID in pain was achieved by 59% of patients at rest and 45% during activity, and a substantial reduction of ≥50% by 45% and 28%, respectively.

Although the proportion of patients with severe activity-related pain (VASmax ≥7) decreased from 83% to 45%, nearly half of patients continued to experience severe pain during activity at 12 months.

Symptoms of PIPS like pubalgia prevalence decreased from 100% at baseline to 56.2% at 12 months ($p = 0.023$). While hyperalgesia of the skin showed a downward trend, it did not reach statistical significance ($p = 0.074$ at 12 months follow-up). The results demonstrate improvements in both functional and pain outcomes over 12 months of follow-up. However, treatment results varied substantially across patients, with some experiencing marked improvement whereas others derived limited or no benefit. These findings suggest that the procedure may have a role in the management of carefully selected patients with refractory PIPS and underline the complexity of this condition.

The potential benefits of surgical intervention in refractory PIPS should always be weighed against its risks. In a small series by Grace et al., in which wedge resection of the symphysis pubis was performed for osteitis pubis, all ten patients initially showed clinical improvement and 70% remained satisfied after a mean follow-up of 92 months [8]. Nevertheless, one patient developed pelvic instability that ultimately required bilateral sacroiliac arthrodesis, illustrating that procedures involving resection of the pubic bone can carry a risk of major complications.

In the present study, no pelvic instability or other major complications (Clavien-Dindo IV or V) were observed, and 44 patients (73.3%) had an uncomplicated postoperative course. However, 16 patients (26.7%) experienced complications, graded as Clavien-Dindo I–III. This rate is considerable, particularly given that the majority of patients did not reach good function (≥75 points) on the HAGOS and nearly half of patients (45%) continued to report severe activity-related pain at 12 months. Possible contributing factors include the location of the wound in the groin, the formation of cavities prone to haematoma, and surgery in previously operated tissue.

Thus, although periosteal stripping does not involve resection of the pubic bone and was not associated with major complications in this series, the risk of complications is not negligible in relation to the benefits achieved, and should be explicitly discussed with patients.

In addition, the morbidity of the procedure should be considered in the interpretation of the results, particularly the risk of hernia recurrence. The medial fibres of the inguinal (Poupart's) ligament and their pubic attachments contribute to the floor of the inguinal canal and often serve as fixation points in anterior mesh repairs. Their deliberate release may therefore further compromise the integrity of the anterior abdominal wall in patients with a history of inguinal hernia repair.

Evidence on this risk is scarce. In the case series of Mehin et al., which included pubic wedge resection or tissue debridement in non-athlete patients, the inguinal ligament was not released and no inguinal hernia recurrences were reported [14]. After primary mesh repair, recurrence rates of approximately 2% are generally reported [15].

In the present study, one patient (1.7%) developed a recurrent inguinal hernia during the 1-year follow-up, and four additional patients (6.7%) developed a recurrence within 2 years, resulting in a cumulative recurrence rate of 8.3%. Three of these five patients had previously undergone mesh removal. This suggests that prior mesh removal may also have contributed considerably to the risk of recurrence. Nevertheless, recurrences also occurred in patients without prior mesh removal, and the overall rate appears higher than the approximately 2% generally reported after primary mesh repair [15].

Direct comparison with primary repair is limited, and a causal relationship between release of the inguinal ligament or prior mesh removal and hernia recurrence cannot fully be established. However, such a relationship remains anatomically plausible and warrants careful consideration. The potential for iatrogenic weakening of the anterior abdominal wall should therefore be carefully weighed against the expected benefits, and patients should be explicitly informed about the risk of hernia recurrence before surgery.

Beyond complication risks, persistent or recurrent complaints after the proposed intervention underscore the complexity and possible multifactorial nature of PIPS, and thereby the difficulty of addressing all potential pain generators with a single procedure. Although postoperative PIPS in non-athletes can potentially be considered a distinct entity, its clinical presentation may overlap with other causes CPIP, such as osteitis pubis, inguinal- and adductor-related pathology, and CPIP resulting from mesh-related pathology or neuropathic pain due to nerve injury.

The evidence for surgical treatment of pubic-related groin pain is limited to case reports and case series, and no single treatment has been shown to be superior [16]. Even after symphyseal curettage in athletes with refractory osteitis pubis, a subset of patients continued to experience symptoms requiring further treatment [17, 18]. Recent anatomical work may partly explain this complexity, describing the pubic region as a complex of closely related ligaments and tendons, each of which may act as a potential pain generator [19].

The present procedure mainly addresses the structures attached to the superolateral aspect of the pubic bone. The insertion of the medial fibers of the inguinal ligament and part of the lateral rectus abdominis insertion at the pubic tubercle are released, and the periosteum of the anterior pubic surface is stripped up to the origin of the adductor longus. The structures attached to the inferomedial aspect of the pubic bone, including the adductor conjoint tendons and the anterior and inferior pubic ligaments [19], as well as the pubic symphysis, are not addressed. These structures may therefore remain potential pain generators after surgery.

In addition, the cohort was heterogeneous with respect to previous treatment. Both anterior (61.7%) and preperitoneal (38.3%) mesh repairs had been performed. As well as, at least 58.3% of patients had undergone neurectomy and 30.0% mesh removal, with incomplete records for some patients. This makes it difficult to establish a single pathophysiological explanation, although all patients presented with a similar clinical pattern of localized pubic tenderness. After periosteal stripping, one patient (1.7%) underwent redo periosteal stripping within the 1-year follow-up because of persistent complaints, five additional patients (8.3%) underwent redo surgery thereafter, and five patients (8.3%) underwent mesh removal because persistent pain was hypothesised to originate from mesh-related pathology.

These findings suggest that persistent symptoms after surgery may reflect overlapping pain generators, including structures not addressed by the present procedure, rather than failure of a single procedure alone. Which structures are primarily responsible for PIPS remains to be clarified in future anatomical and imaging studies.

These findings suggest that persistent symptoms after surgery may reflect overlapping pain generators, including structures not addressed by the present procedure, rather than failure of a single procedure alone. Which structures are primarily responsible for PIPS remains to be clarified in future anatomical and imaging studies.

This diagnostic complexity is further illustrated by the hypothesis that MRI may play a limited diagnostic role in this study population, as it rarely demonstrates the characteristic findings observed in athletic populations, suggesting a potentially different underlying pathological substrate. In athletes with pubic periostitis, MRI is the preferred imaging modality, typically revealing bone marrow oedema on fat-suppressed T2-weighted sequences with high sensitivity and specificity for identifying degenerative pubic changes [20–22]. In the present study, preoperative MRI was performed in all patients (100%) to exclude alternative pathology. Only four MRI scans showed abnormalities, with a cleft sign identified in one case (1.7%), sclerosis surrounding the pubic bone observed in one other case (1.7%), and enthesitis or enthesopathy present in two cases (3.3%). None of the patients exhibited classic bone marrow oedema, which may argue against an active inflammatory process as the primary pathological substrate.

In the present cohort, using standard MRI protocols, MRI showed limited benefit in confirming the diagnosis of PIPS in post-hernia repair patients. However, recent studies suggest that dedicated imaging planes may improve the assessment of the pubic ligaments and tendinous attachments [23], which may provide further insight into future studies. Meanwhile, MRI remains a valuable tool for excluding alternative causes of chronic groin pain and should be interpreted within the appropriate clinical context.

Several limitations of the present study warrant consideration. Firstly, follow-up data were incomplete, and the proportion of missing data varied across time points, reaching 65% at 9 months and 45% at 12 months for the primary outcome (HAGOS). Missing data may have been related to treatment outcome. Patients who were satisfied with their outcome may have been less likely to respond to follow-up assessments, which would lead to an underestimation of the improvement. Conversely, patients with persistent complaints may have been less motivated to participate, which would lead to an overestimation. In addition, the COVID-19 pandemic limited outpatient visits during part of the study period. Although follow-up was partly conducted through online questionnaires and non-responders were contacted by telephone, these factors may have contributed to the relatively low response rate.

To make optimal use of the available data, outcomes were analysed using linear mixed models, which included all available observations of each patient. Although linear mixed modelling can account for incomplete repeated measurements under a missing-at-random assumption, response bias cannot be fully excluded. Furthermore, responder rates and pain severity categories could only be calculated for patients with data available both pre-operatively and at 12 months, which further reduced the number of patients in these analyses.

Secondly, this study was designed to evaluate patients with PIPS after inguinal hernia repair. An inguinal hernia prior to the index operation was documented in 65% of patients, either clinically or by ultrasonography, whereas information on the presentation preceding the index repair could not be retrieved for the remaining 35%. Therefore, it cannot be excluded that a minority of patients already experienced groin or pubic pain before their hernia repair, possibly reflecting a pre-existing musculoskeletal or pubic pain syndrome rather than a postoperative condition.

A further limitation concerns the outcome measure employed. The HAGOS was used to assess hip and groin pain. However, this instrument was originally validated in Dutch by Giezen et al. in a cohort of patients with hip pathology, rather than in patients with PIPS specifically [24]. Consequently, its validity as an outcome measure in this distinct patient population remains uncertain. Future development and validation of a disease-specific patient-reported outcome measure for PIPS patients would therefore be warranted.

Despite these limitations and discussion points, the present study provides a basis for future research directions that may further advance the understanding and management of PIPS.

First of all, in the current study no histological evaluation was performed during surgery, as routine pathology was not anticipated to yield clinically relevant findings in this setting. However, histological analysis may be worthwhile for future research, as characterization of the tissue removed during periosteal stripping could provide insight into the underlying pathophysiology of PIPS. It remains an open question whether the tissue responsible for pain generation in these patients demonstrates distinct histological features, and such findings could contribute to a better understanding of the mechanism of chronic postoperative inguinal pain in non-athletes.

In addition, long-term follow-up studies with standardized outcome measures and larger sample sizes are needed to evaluate the durability of the surgical effect and to determine whether the observed improvements in pain and functional outcomes are sustained or subject to decline in the years following the intervention. Such studies would furthermore provide greater insight into the long-term complication profile associated with this intervention.

In conclusion, anterior pubic periosteal stripping with release of the inguinal (Poupart's) ligament and the lateral rectus abdominis muscle attachment may improve hip and groin function and reduce pain in non-athlete patients with a history of inguinal hernia repair

and PIPS refractory to all prior conservative and surgical management. More than half of patients achieved a clinically important reduction in pain at rest, and nearly half during activity, while approximately one in four experienced a substantial (≥50%) reduction in activity-related pain. However, nearly half of patients continued to experience severe pain during activity, and fewer than half reached good hip and groin function at 12 months. Given the anatomical complexity of the operative field and the non-negligible incidence of minor to moderate complications, including potential weakening of the anterior abdominal wall and recurrent inguinal hernia, comprehensive preoperative counselling is essential. The potential benefits should be carefully weighed against these risks together with the patient. Nonetheless, in carefully selected patients with refractory PIPS in whom all other therapeutic options have been exhausted, this technique may be considered a last-resort treatment option.

Data availability statement

The raw data supporting the conclusions of this article will be made available by the authors upon reasonable request, in anonymised form.

Ethics statement

The studies involving humans were approved by Maxima Medical Centre ethics committee. The studies were conducted in accordance with the local legislation and institutional requirements. The participants provided their written informed consent to participate in this study.

Author contributions

MS, RR, and PE contributed to the conception and design of the study. MS, RR, WZ, and PE performed the surgical procedures. PE and JR collected and analysed the data. JR, WZ, and PE drafted the manuscript. All authors contributed to the article and approved the submitted version.

Funding

The author(s) declared that financial support was not received for this work and/or its publication.

Conflict of interest

The author(s) declared that this work was conducted in the absence of any commercial or financial relationships that could be construed as a potential conflict of interest.

Generative AI statement

The author(s) declared that generative AI was used in the creation of this manuscript. Generative AI was used to assist in creating the schematic illustration in Figure 1, which was edited and verified by the authors, who take full responsibility for its content.

Any alternative text (alt text) provided alongside figures in this article has been generated by Frontiers with the support of artificial intelligence and reasonable efforts have been made to ensure accuracy, including review by the authors wherever possible. If you identify any issues, please contact us.

Publisher's note

All claims expressed in this article are solely those of the authors and do not necessarily represent those of their affiliated organizations, or those of the publisher, the editors and the reviewers. Any product that may be evaluated in this article, or claim that may be made by its manufacturer, is not guaranteed or endorsed by the publisher.

References

1. Campanelli G. Pubic inguinal pain syndrome: the so-called sports hernia. *Hernia* (2010) 14(1):1–4. doi: 10.1007/s10029-009-0610-2

2. Cavalli M, Bombini G, Campanelli G. Pubic Inguinal Pain Syndrome: The So-Called Sports Hernia. *Surg Technol Int* (2014) 24:189–94.

3. Gomella P, Mufarrij P. Osteitis pubis: a rare cause of suprapubic pain. *Rev Urol* (2017) 19(3):156–63. doi: 10.3909/riu0767

4. Gonik B, Stringer CA. Postpartum osteitis pubis. *South Med J* (1985) 78(2):213–4. doi: 10.1097/00007611-198502000-00028

5. Zwaans WAR, Scheltinga MRM, Roumen RMH. Aetiology, pathogenesis and assessment of chronic pain after inguinal hernia repair. In: Campanelli G, editor. *The Art of Hernia Surgery*. Cham: Springer (2018). p. 397–416. doi: 10.1007/978-3-319-72626-7_41

6. Loos MJA, Roumen RMH, Scheltinga MRM. Classifying post-herniorrhaphy pain syndromes following elective inguinal hernia repair. *World J Surg* (2007) 31(9):1760–5. doi: 10.1007/s00268-007-9121-4

7. HerniaSurge Group. International guidelines for groin hernia management. *Hernia* (2018) 22(1):1–165. doi: 10.1007/s10029-017-1668-x

8. Grace JN, Sim FH, Shives TC, Coventry MB. Wedge resection of the symphysis pubis for the treatment of osteitis pubis. *J Bone Joint Surg Am* (1989) 71(3):358–64. doi: 10.2106/00004623-198971030-00008

9. Zwaans WA, Scheltinga MRM, Puylaert JB, Roumen RMH. Mesh removal and selective neurectomy for persistent groin pain following lichtenstein repair. *World J Surg* (2017) 41(3):701–12. doi: 10.1007/s00268-016-3780-y

10. Andresen K, Rosenberg J. Management of chronic pain after hernia repair. *J Pain Res* (2018) 11:675–81. doi: 10.2147/JPR.S127820

11. de Queiroz RD, Neto IB, Schickert M, Pires PR, da Silva JL, Bittencourt NFN. Return to sport after surgical treatment for pubalgia among professional soccer players. *Rev Bras Ortop* (2014) 49(3):233–9. doi: 10.1016/j.rboe.2014.04.001

12. Farrar JT, Young JP, Jr, LaMoreaux L, Werth JL, Poole RM. Clinical importance of changes in chronic pain intensity measured on an 11-point numerical pain rating scale. *Pain* (2001) 94(2):149–58. doi: 10.1016/S0304-3959(01)00349-9

13. Dworkin RH, Turk DC, Wyrwich KW, Beaton D, Cleeland CS, Farrar JT, et al. Interpreting the clinical importance of treatment outcomes in chronic pain clinical trials: IMMPACT recommendations. *J Pain* (2008) 9(2):105–21. doi: 10.1016/j.jpain.2007.09.005

14. Mehin R, Meek R, O'Brien P, Blachut P. Surgery for osteitis pubis. *Can J Surg* (2006) 49(3):170–6.

15. Lockhart K, Dunn D, Teo S, Ng JY, Dhillon M, Teo E, et al. Mesh versus non-mesh for inguinal and femoral hernia repair. *Cochrane Database Syst Rev* (2018) 9:CD011517. doi: 10.1002/14651858.CD011517.pub2

16. Choi H, McCartney M, Best TM. Treatment of osteitis pubis and osteomyelitis of the pubic symphysis in athletes: a systematic review. *Br J Sports Med* (2011) 45(1):57–64. doi: 10.1136/bjsm.2008.050989

17. Mulhall KJ, McKenna J, Walsh A, McCormack D. Osteitis pubis in professional soccer players: a report of outcome with symphyseal curettage in cases refractory to conservative management. *Clin J Sport Med* (2002) 12(3):179–81. doi: 10.1097/00042752-200205000-00006

18. Radic R, Annear P. Use of pubic symphysis curettage for treatment-resistant osteitis pubis in athletes. *Am J Sports Med* (2008) 36(1):122–8. doi: 10.1177/0363546507306160

19. Mathieu T, Van Glabbeek F, Denteneer L, Van Winckel L, Schacht E, De Vlam B, et al. New anatomical concepts regarding pubic-related groin pain: a dissection study. *Ann Anat* (2024) 254:152238. doi: 10.1016/j.aanat.2024.152238

20. Gaudino F, Spinelli MS, Stilo FL, Smaldone MC, Marziali V, Conserva V, et al. Osteitis pubis in professional football players: MRI findings and correlation with clinical outcome. *Eur J Radiol* (2017) 94:46–52. doi: 10.1016/j.ejrad.2017.07.009

21. Todeschini K, Daruge P, Bordalo M, Cerezal L, Marques FS, Schmidt CM, et al. Imaging assessment of the pubis in soccer players. *Rev Bras Ortop (Sao Paulo)* (2019) 54(2):118–27. doi: 10.1016/j.rbo.2017.12.012

22. Omar IM, Zoga AC, Kavanagh EC, Koulouris G, Bergin D, Gopez AG, et al. Athletic pubalgia and "sports hernia": optimal MR imaging technique and findings. *Radiographics* (2008) 28(5):1415–38. doi: 10.1148/rg.285075217

23. Mathieu T, Van Glabbeek F, Van Nassauw L, Denteneer L, Bouziotis J, Van Dyck P. Inferior pubic ligament injury: magnetic resonance imaging assessment in athletes with pubic-related groin pain. *Orthop J Sports Med* (2025) 13(9):23259671251380879. doi: 10.1177/23259671251380879

24. Giezen H, Stevens M, van den Akker-Scheek I, Reininga IHF, Diercks RL, van Beveren J. Validity and reliability of the Dutch version of the copenhagen hip and groin outcome score (HAGOS-NL) in patients with hip pathology. *PLoS One* (2017) 12(10):e0186064. doi: 10.1371/journal.pone.0186064