

Cytomegalovirus infection accelerates cardiac allograft vasculopathy: correlation between angiographic and endomyocardial biopsy findings in heart transplant patients

Petri K. Koskinen¹, Markku S. Nieminen², Leena A. Krogerus¹, Karl B. Lemström¹, Severi P. Mattila³, Pekka J. Häyry¹, Irmeli T. Lautenschlager¹

¹ Transplantation Laboratory, P.O. B. 21 (Haartmaninkatu 3), SF-00014 Helsinki, Finland

² First Department of Medicine, Helsinki University Central Hospital, Haartmaninkatu 3, SF-00290 Helsinki, Finland

³ Department of Thoracic and Cardiovascular Surgery, Helsinki University Central Hospital, Haartmaninkatu 3, SF-00290 Helsinki, Finland

Received: 27 October 1992/Received after revision: 11 February 1993/Accepted: 25 February 1993

Abstract. In order to determine the impact of cytomegalovirus (CMV) infection on cardiac allograft vasculopathy (CAV), we quantitated angiograms and endomyocardial biopsy (EMB) specimens obtained from 53 heart transplant recipients. CMV infection was particularly associated with the development of discrete stenosis in major branch vessels ($P < 0.03$). Also, the number of diffusely affected vessel segments was significantly higher in CMV patients than in CMV-free recipients after the 2nd postoperative year ($P < 0.05$). The EMB histology correlated well with angiography. Significantly higher levels of arteriolar endothelial cell proliferation and intimal thickness were recorded in biopsies of CMV patients than in those of CMV-free recipients during the 1st postoperative year ($P < 0.02$ and $P < 0.005$, respectively). The CMV-associated vascular changes in EMB histology clearly preceded angiographically detectable CAV findings. Taken together, CMV infection accelerated heart allograft arteriosclerosis. The histological changes appeared prior to changes detected by coronary angiography. The CMV effect was particularly pronounced during the first 2 post-transplant years but leveled off thereafter. Thus, CMV-accelerated allograft arteriosclerosis may be linked in particular with early graft loss of CMV-infected heart transplant recipients.

Key words: Cytomegalovirus, heart transplantation – Heart transplantation, CMV infection – Endomyocardial biopsy, CMV infection – Vasculopathy, CMV infection

Introduction

Accelerated allograft arteriosclerosis (chronic rejection) has emerged as a major factor affecting allograft survival in the long run [1, 4]. It is the main cause of death after the 1st post-transplant year. In coronary angiography, the in-

cidence of cardiac allograft vasculopathy (CAV) is between 6 % and 18 % at 1 year, about 23 % at 2 years, and up to 50 % at 5 years [9, 18].

Coronary arteries of cardiac allografts with prolonged survival often present a distinctive angiographic appearance, as reported previously [9]. Proximal, focal lesions with asymmetric atherosclerotic plaques identical to those occurring in classical atherosclerosis are observed, but diffuse, concentric, luminal narrowing, which affects the entire length of the vessel wall including small penetrating intramyocardial branches, is often seen [4], unlike in non-transplant patients with coronary artery disease (CAD).

Cytomegalovirus (CMV) infection is an important cause of morbidity and mortality in heart allograft recipients [6]. Recently, increasing evidence has been reported indicating a role for CMV in the pathogenesis of CAV [10, 16, 17]. An association between CMV infection, allograft rejection, and graft atherosclerosis has been suggested [10]. In addition, CMV nucleic acids have been identified in coronary arteries of heart transplant recipients with severe CAV [14]. Finally, CMV has been demonstrated in arterial walls of nontransplant patients with coronary artery disease [12].

In this communication, we describe the association of CMV infection with early and accelerated development of CAV throughout the allograft vascular tree, as revealed by a semiquantitative analysis of vasculopathic changes in angiograms and endomyocardial biopsy (EMB) specimens of heart transplant patients.

Patients and methods

Patients

Fifty-three heart allograft recipients who were monitored for CMV infection and who survived for at least 1 year after cardiac transplantation were included in the study. A total of 115 angiograms and 104 EMBs obtained from these patients were analyzed. Basic immunosuppression consisted of cyclosporin A, prednisolone, and azathioprine in all recipients. Antithymocyte globulin (ATG, 1 mg/kg, Fresenius) was given for 3 days postoperatively. Rejection episodes

were diagnosed by EMB histology and graded according to the working formulation of the International Society of Heart Transplantation [5]. Rejection episodes were treated with methylprednisolone (MP), ATG, or both. CMV hyperimmune globulin prophylaxis (Cytotect, 1 ml/kg per day) was preoperatively given to CMV-seronegative patients. All patients also received acyclovir prophylaxis (600 mg/day p.o.) against herpes virus infections for the first 3 months. In the case of severe symptomatic CMV infection, ganciclovir (Cymevene, 10 mg/kg per day), CMV hyperimmune globulin (Cytotect, 2 ml/kg per day), or both were administered. Aspirin (100 mg/day) was postoperatively given to all patients.

Cardiac catheterization and coronary angiography

All patients were evaluated annually with selective coronary angiography using the percutaneous femoral approach. Graft function was independently evaluated by echo cardiography. On the basis of previous studies [9] and a pilot study of ten angiograms of transplanted hearts, a list of descriptors for coronary arteriolar morphological changes was created.

Stenosis. Discrete stenosis was assessed from the proximal (_p), middle (_m), and distal (_d) part of large, epicardial vessels including left main (LCA), left anterior descending (LAD), left circumflex (LCX), and right coronary (RCA) artery, as well as from the major branches of large, epicardial vessels including the major left diagonal (LD), left obtuse marginal (LOM), right ventricular (RV), right posterior descending (RPD) and right posterolateral branches (RPL). The reduction in luminal cross-section was measured by comparing the narrowed region to an adjacent, angiographically normal region.

Table 1. Patient characteristics. CM, Cardiomyopathy; ICHD, ischemic coronary heart disease; BP, blood pressure; B-CyA, blood cyclosporin A level

| | CMV group | Control group | Significance ^{b, c} |
|-------------------------------------|-----------|---------------|------------------------------|
| Original disease | | | |
| -CM | 11 | 17 | NS ^b |
| -ICHD | 17 | 6 | NS ^b |
| -Congenital | 1 | 1 | NS ^b |
| Age (years) | 45 ± 10 | 46 ± 12 | NS ^c |
| Gender (M/F) | 27/2 | 21/3 | NS ^b |
| Systolic BP ^a (mmHg) | 135 ± 14 | 140 ± 13 | NS ^c |
| Diastolic BP ^a (mmHg) | 88 ± 11 | 87 ± 10 | NS ^c |
| S-cholesterol ^d (mmol/l) | 6.3 ± 1.5 | 5.7 ± 1.2 | NS ^c |
| B-CyA ^{a, d} (µg/l) | 228 ± 75 | 237 ± 46 | NS ^c |

^a Determined at 1 year post-transplantation

^b Chi-square test with Yates' correction

^c Mann-Whitney U-test correcting for ties

^d No CyA toxicity was observed

Table 2. The number of angiograms analyzed and the frequency of cardiac allograft vasculopathy (CAV) detected during the 4 post-transplant years

| | Year after cardiac transplantation | | | |
|-------------------------|------------------------------------|------|------|------|
| | 1 | 2 | 3 | 4 |
| Angiograms | 50 | 31 | 25 | 9 |
| CMV patients | 28 | 19 | 16 | 5 |
| CAV _{total} | 16 % | 39 % | 52 % | 56 % |
| CAV _{CMV} | 25 % | 53 % | 56 % | 60 % |
| CAV _{CMV-free} | 5 % | 17 % | 44 % | 50 % |

Diffuse disease. This was defined as the gradual transition from a proximal, large epicardial or major branch vessel to a concentrically narrowed, middle, and distal part with diffuse, irregular vessel boundaries and a loss of fine branches.

Cardiac allograft vasculopathy (CAV). CAV was defined as any evidence of stenosis or diffuse disease in any vessel.

In order to compare patients, a scoring system was developed and scores were calculated as follows: Discrete stenosis were assessed from LCA, LAD_{pmd}, LCX_{pmd}, RCA_{pmd}, from their branches designated as LOM I, II, III, LD 1, 2, RV, RPD, and RPL and marked as present (score 1) or absent (score 0). A diffuse disease score was calculated in a similar fashion from the same segments and their small branches. Thus, theoretically, these scores would range from 0 to 18. Finally, a total score, attributable to CAV, was calculated as the sum of scores of both discrete stenosis and diffuse disease.

Demonstration of CMV infection

Altogether 11 recipients were CMV-seronegative and 36 CMV-seropositive before transplantation; in 6 recipients the preoperative anti-CMV antibody status was unknown. Thirty-three of the donors were CMV-seropositive and 14 CMV-seronegative; in 6 donors the anti-CMV antibody status was unknown. Eight of the CMV-seronegative recipients received their grafts from a seropositive donor. After transplantation the recipients were monitored routinely for anti-CMV antibodies by a complement fixation test (CF), weekly during the first 3 months, once in 2 weeks during months 4–6, and then yearly. Specific anti-CMV IgG and IgM antibodies (ELISA, Labsystems) and a viral culture from urine were determined at 3, 6, 9, and 12 postoperative months. The virological diagnosis of CMV infection was based on specific IgM or a positive viral culture from blood, urine, or bronchoalveolar lavage (BAL) fluid, together with a fourfold rise in IgG. Since the method for detecting CMV-specific antigens on blood leukocytes became available, all recipients were monitored for CMV antigenemia. For the detection of CMV in blood leukocytes a modification of the original method was used [3].

Endomyocardial biopsies

EMBs were performed weekly for the first 3 weeks, thereafter twice a month during months 1–3, then at monthly intervals until the 6th month, and thereafter every 2 months until the 12th postoperative month. After the 1st postoperative year, EMBs were performed every 6th month. Three to six endomyocardial fragments per biopsy were obtained using the 7-F biptome. Specimens with fewer than three fragments were excluded. Specimens were fixed in 10% buffered formalin, processed routinely, and stained with Masson's trichrome, hematoxylin and eosin, toluidine blue, and Unna-Pappenheim (UP). Three-micrometer-thick sections were cut serially and three to five consecutive sections were placed on each slide.

Scoring principles

The slides were reviewed retrospectively in a blinded fashion by two observers without knowledge of the angiographic findings. The analysis was done semiquantitatively. The histological parameters of intramyocardial vessels were graded from 0 to 3: 0 normal, 1 mild, 2 moderate, and 3 severe.

Intramyocardial vessels. Vessels with well-defined surrounding smooth muscle cells in the walls were identified as "arterioles", whereas those without a smooth muscle cell layer were considered "capillaries". Endothelial cell proliferation was scored mild when endothelial cells were closely packed in one layer, moderate in two, and severe with three closely packed cell layers. Arteriolar intima was

defined as an acellular layer immediately beneath the endothelium and was normally not seen (score 0). The intimal thickness was scored as mild when intima was readily discernible and moderate to severe when arteriolar lumen was moderately to severely compromised.

Statistical methods

Data are expressed as mean \pm SEM, if not otherwise indicated. For comparison of results between patient groups, the chi-square test with Yates' correction and Mann-Whitney U-test correcting for ties were used. *P* values less than 0.05 were considered significant.

Results

CMV infections and frequency of acute rejections

In 29 of 53 patients (55%), CMV infection was diagnosed 68 ± 39 (mean \pm SD) days postoperatively (Table 1). Seven primary infections and 19 reactivations/reinfections were recorded. In three cases the preoperative, serological CMV antibody status was unknown. Symptomatic CMV infection occurred in ten patients (34%). Four CMV infections were considered severe and treated with ganciclovir, one combined with CMV hyperimmune globulin. No difference in CAV findings was observed between recipients with primary CMV infection or reactivation/reinfection.

Neither the frequency nor the severity of acute rejections differed significantly between CMV and CMV-free recipients. In CMV patients, 29 EMBs showed evidence of rejection (one rejection/patient, range 0–5) 265 ± 294 (mean \pm SD) days postoperatively. Rejections were mostly mild (grades 1A or 1B); only two grade 3A rejections occurred. In CMV-free recipients, acute rejection was diagnosed in 27 EMBs (1.5 rejections/patient, range 0–6) 421 ± 436 (mean \pm SD) days postoperatively. Most rejections were mild; only 1 grade 3A rejection was seen.

Angiographic findings

Frequency of CAV

CMV infection was associated with early accelerated allograft arteriosclerosis (Table 2). Even after the 1st post-transplant year, CAV was markedly, although not significantly, more frequent in CMV patients than among CMV-

free recipients. After 2 years postoperatively, more than half of the CMV-infected patients had evidence of CAV, whereas only a minority of the CMV-free patients had abnormal angiograms (*P* = NS). Thereafter, CAV was seen in approximately equal frequency in both patient groups.

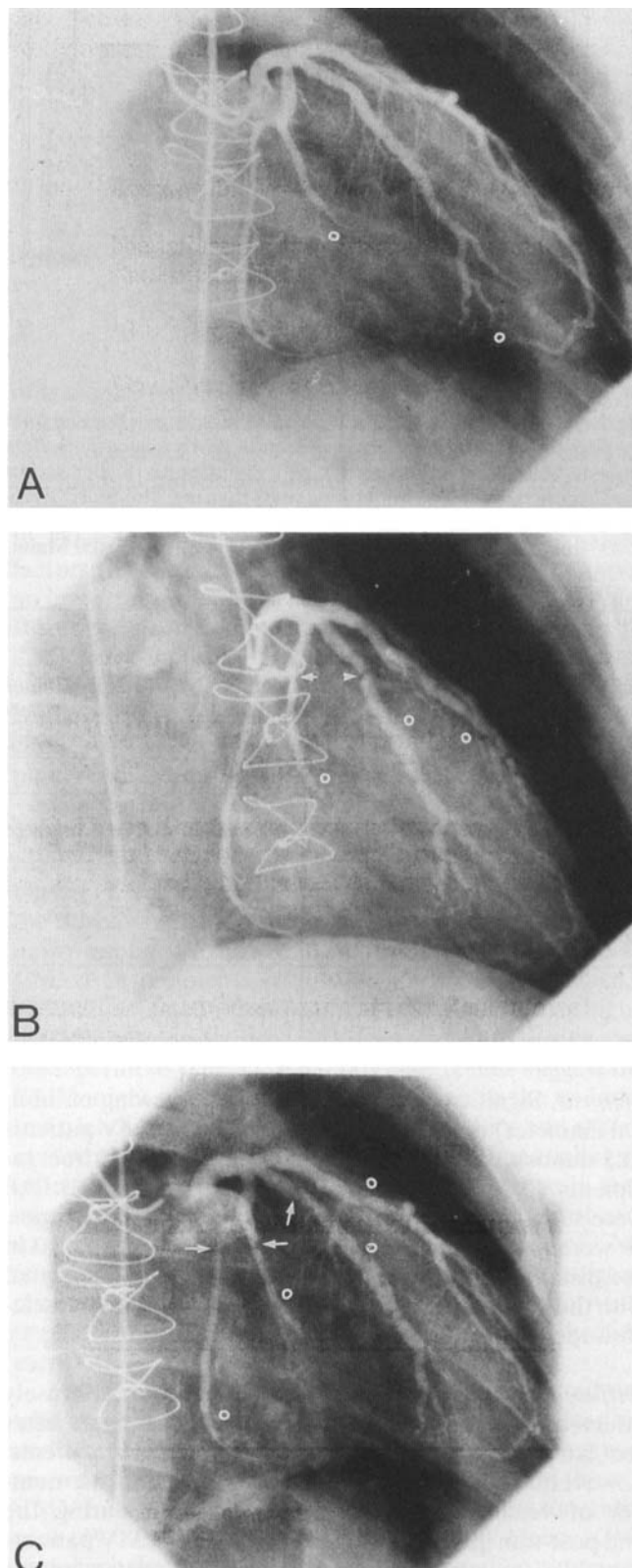


Fig. 1A–C. Left coronary artery angiograms of a CMV patient at **A** 1 year, **B** 2 years, and **C** 4 years after cardiac transplantation. Already after the 1st postoperative year, diffuse disease (o) was seen in distal parts of the left anterior descending (LAD) artery and in the left obtuse marginal (LOM I and II) branches (score 6). A dramatic acceleration of CAV occurred during the subsequent year; severe discrete stenosis (arrow) developed in LOM I and LOM II. The angiogram showed marked concentric narrowing with irregular vessel boundaries and loss of fine branches in the proximal, middle, and distal parts of LAD and LOM I and II (score 14). After 4 years postoperatively, the acceleration of CAV had leveled off and a new mild stenosis was seen in the left circumflex coronary artery (LCX). LAD, LOM I, II and the middle and distal parts of LCX were diffusely affected (score 16)

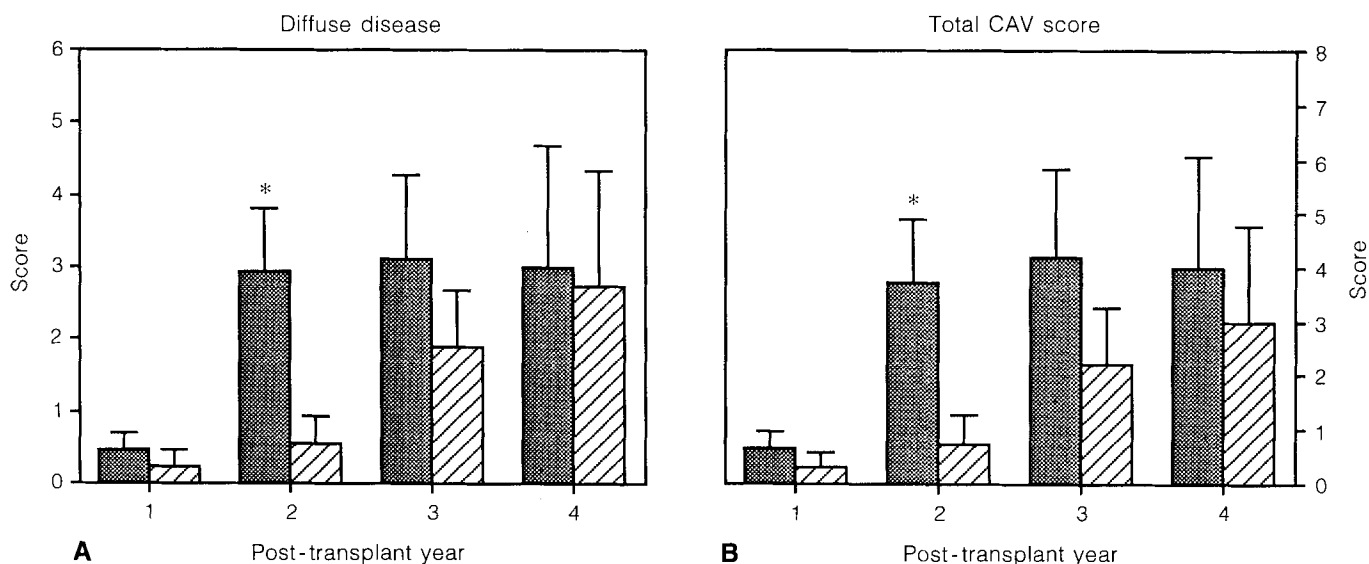


Fig. 2. **A** Mean scores of diffusely affected vessels and **B** mean total CAV scores of heart transplant recipients in yearly angiograms. Bars indicate SEM. In CMV patients (■), significantly higher scores were recorded after 2 postoperative years than in CMV-free (▨) recipients. Thereafter, the difference with vasculopathic changes in CMV-free recipients was no longer significant. * $P < 0.05$; Mann-Whitney U-test

Table 3. The number of endomyocardial biopsy (EMB) specimens analyzed and the frequency of vascular changes (VC) observed during the 4 post-transplant years

| | Year after cardiac transplantation | | | |
|------------------------|------------------------------------|------|-------|-------|
| | 1 | 2 | 3 | 4 |
| EMBSs | 43 | 28 | 25 | 8 |
| CMV patients | 26 | 19 | 16 | 4 |
| VC _{total} | 74 % | 79 % | 88 % | 100 % |
| VC _{CMV} | 77 % | 84 % | 81 % | 100 % |
| VC _{CMV-free} | 71 % | 67 % | 100 % | 100 % |

Intensity of CAV

Stenosis. Significant stenosis ($\geq 50\%$ narrowing of luminal diameter) occurred more frequently in CMV patients (0.7 stenosis/patient, range 0–7) than in CMV-free recipients (0.1 stenosis/patient, range 0–2; $P < 0.03$). All were seen in major branches of large epicardial arteries; 19 were located in the proximal, 2 in the middle and 3 in the distal segment. Thus, CMV infection was associated with the development of a severe form of graft arteriosclerosis recorded as discrete coronary vessel stenosis (Fig. 1).

Diffuse disease. Only very few vessels were diffusely affected in both CMV and CMV-free recipients after the 1st post-transplant year (Fig. 2). In CMV patients, however, there was an accelerated increase in the number of vessel segments diffusely affected during the 2nd post-transplant year: the mean score of CMV patients was 3.0 ± 0.5 versus 0.5 ± 0.4 for CMV-free recipients

($P < 0.05$). During subsequent years, the CMV-associated acceleration of diffuse disease was seen to level off.

Total scores. Considering stenosis and diffuse disease together, the total scores of the patients (Fig. 2) presented a pattern similar to that of diffuse disease, with significantly higher mean scores for CMV patients after the 2nd post-transplant year than for CMV-free recipients ($P < 0.05$). Due to more frequent stenosis in CMV patients, the difference with vasculopathic changes in CMV-free recipients leveled off markedly, but not entirely.

Histological findings

The frequency of vascular changes (VC) in EMBs was significantly higher than in angiograms during the first 3 postoperative years (1st year: $P < 0.001$; 2nd year: $P < 0.005$; 3rd year: $P < 0.03$; Table 3). Capillary endothelial cell proliferation was common in both patient groups, and no difference in overall frequency of VC in EMBs between CMV and CMV-free patients was observed. However, the histology of small intramyocardial arterioles revealed CMV-associated changes.

Arteriolar endothelial cell proliferation. Closely packed endothelial cells in two or more layers, scored moderate to severe, were a characteristic feature of CMV patients (Fig. 3). A significant difference in the scores of endothelial cell proliferation was recorded between CMV and CMV-free recipients after the 1st postoperative year ($P < 0.02$). Thereafter, this proliferative cell response became less prominent.

Intimal thickening. Thickened intimas that narrowed the lumens of small intramyocardial arterioles appeared early in CMV patients (Fig. 4). Scores of intimal thickness were significantly higher among CMV patients after the 1st and 2nd postoperative years than among CMV-free recipients ($P < 0.005$ and $P < 0.05$, respectively; Fig. 3). During sub-

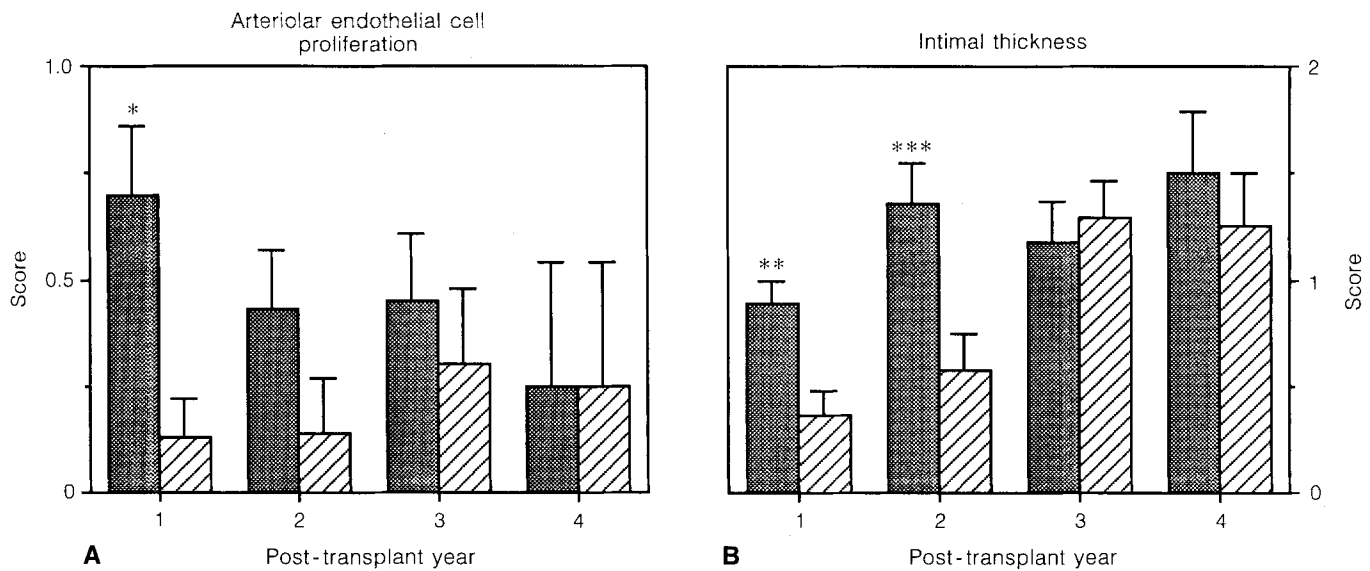


Fig. 3A,B Mean scores of **A** arteriolar endothelial cell proliferation and of **B** intimal thickness of heart transplant recipients in yearly EMBs. Bars indicate SEM. In CMV patients (■), significantly higher scores of endothelial cell proliferation and intimal thickness were recorded during the 1st postoperative years than in CMV-free (▨) recipients. * $P < 0.02$, ** $P < 0.005$, *** $P < 0.05$; Mann-Whitney U-test

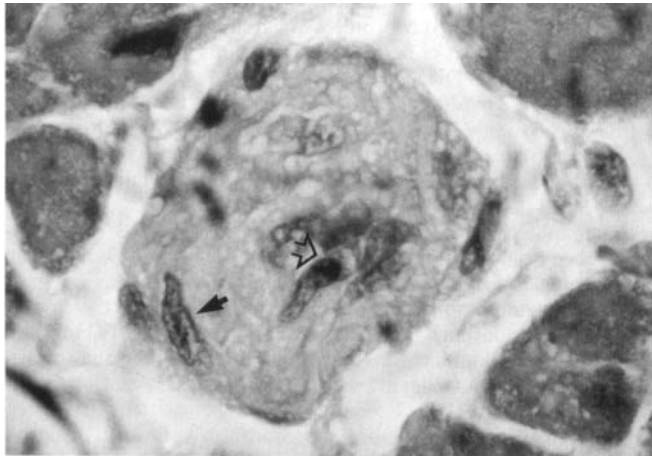


Fig. 4. Severe intimal thickening (score 3) with a nearly occluded arteriolar lumen in an EMB of a CMV patient 2 years after cardiac transplantation. Lumen of vessel marked with empty arrow and myocyte with black arrow. Original magnification $\times 860$

sequent years, the intimal thickening of CMV patients reached a plateau, and as the arterioles of CMV-free recipients also began to show evidence of chronic changes, the difference was no longer significant.

Discussion

CAV is a major limiting factor of long-term survival after heart transplantation [1, 4]. Two distinct, angiographically detectable types of vascular lesions have been described

in transplanted hearts [9]. One type includes discrete localized stenosis, virtually indistinguishable from classical arteriosclerosis, whereas the other type, diffuse concentric luminal narrowing, affecting the entire length of the vessel wall including the small intramyocardial branches [9, 15], is identified only in transplanted hearts. Usual risk factors for coronary arteriosclerosis do not seem to play an important role in the development of CAV [4, 13, 20]. Recently, strong clinical evidence indicating a role for CMV infection in the generation of cardiac allograft vasculopathy was obtained [10, 16, 17], although in other studies no association could be found [20, 21]. More recently, the association between CMV viremia and transplant coronary arteriosclerosis was reported [7].

The current study confirms that CMV is associated with the accelerated development of heart allograft arteriosclerosis. The semiquantitated angiography revealed that (1) CMV infection was particularly associated with the development of discrete stenosis identical with that in nontransplant arteriosclerosis when compared with CMV-free recipients ($P < 0.03$), and (2) the number of diffusely affected vessel segments was significantly higher in CMV patients than in CMV-free recipients during early postoperative years ($P < 0.05$). These results suggest that CMV might cause a local lytic infection in the endothelium, leading to local inflammatory reactions and atheroma formation. Also, CMV could enhance the antiallograft inflammatory responses towards the vascular wall, leading to accelerated development of the diffuse type of coronary arteriosclerosis. Therefore, early diagnosis of CMV with rapid laboratory tests, i.e., with the CMV antigenemia assay, and active treatment of the infection would appear to be important steps in preventing the development of CAV.

The semiquantitated EMB histology correlated well with angiography. Significantly higher scores of arteriolar endothelial cell proliferation and intimal thickness were recorded in the EMBs of CMV patients than in those of CMV-free recipients during the very 1st postoperative year ($P < 0.02$ and $P < 0.005$, respectively). Hence, CMV also strongly accelerated CAV in the small intramyocar-

dial vessels. Vascular changes in EMB histology clearly preceded angiographically detectable changes that were most prominent in CMV patients after the 2nd postoperative year. Thereafter, the CMV-associated acceleration of allograft arteriosclerosis reached a plateau, and by the 3rd and 4th postoperative years, both CMV and CMV-free patients had vascular changes in approximately equal amounts. This very essential observation of our study may be explained by previous findings from *in vitro* studies [19], namely, that smooth muscle cells obtained from vascular media undergo *in vitro* replication 35–50 times as do diploid human cells in general [11], whereas smooth muscle cells obtained from atherogenic lesions undergo replication only 2–5 times at the most. Thus, smooth muscle cells seem to have a limited capacity of cell division and may explain why the CMV-induced acceleration of graft arteriosclerosis is self-limiting.

A previous study of 301 heart transplant patients treated with cyclosporin has demonstrated that the percentage of patients surviving 5 years was significantly lower in the CMV group than in the non-CMV group (32% vs 68%, respectively) [10]. Also, the rate of graft loss during this time was significantly higher in CMV patients than in non-CMV patients (69% vs 37%, respectively). Thus, the risk of CMV-associated graft loss is particularly pronounced during the first 5 post-transplant years, a finding that is in complete agreement with the observations reported in this communication. However, in our series, all of the patients who entered the study and, thus, had survived the 1st postoperative year were also alive at the end of the follow-up.

Several possible mechanisms underlying the association between CMV and CAV have been suggested. The virus could directly cause endothelial cell damage and lead to ineffective repair and plaque formation [10]. By infecting smooth muscle cells and endothelial cells in vessel walls, CMV could either autocrinely or paracrinely induce the expression of different growth factors in vessel walls [13]. Also, an increased MHC antigen expression, mediated by interferon-gamma produced during viral infection, has been suggested to trigger a rejection cascade [22]. In addition, DNA sequence analysis has demonstrated that CMV encodes a molecule similar to MHC class I antigen [2]. The molecule has been suggested to bind to beta-2-microglobulin and could thus be involved in virus-cell attachment [2]. Alternatively, this molecule might interfere with the induction of cell-mediated, MHC-restricted immunity and the cytolytic T-cell response to the infected cells. Also, sequence homology and immunological crossreactivity of CMV with the HLA-DR beta chain has been demonstrated [8]. This crossreactivity and the crossreacting antibodies could be involved in allograft rejection mechanisms.

Taken together, our results suggest that CMV infection is associated with the early and accelerated development of CAV in angiograms preceded by CMV-induced vascular changes in EMB histology. This CMV-associated acceleration was particularly prominent during the first 2 postoperative years but reached a plateau thereafter. After the 3rd post-transplant year, the vasculopathic changes were approximately equal

in both the CMV-infected and the noninfected patient groups. The CMV effect might, thus, be linked in particular with early death and graft loss, as has been reported earlier in CMV-infected heart transplant patients [10].

Acknowledgements. This study was supported by grants from the Sigrid Juselius Foundation, the Finnish Academy of Science, and the University of Helsinki.

References

1. Barnart GR, Pascoe EA, Mills AC, Szentpetery S, Eich DM, Mohanakumar T, Hastillo A, Thompson JA, Hess ML, Lower RR (1989) Accelerated coronary arteriosclerosis in cardiac transplant recipients. *Transplant Rev* 1: 31–46
2. Beck S, Barrel BG (1988) Human cytomegalovirus encodes a glycoprotein homologous to MHC class-I antigens. *Nature* 331: 269–272
3. Bij W van der, Torensma R, Son WJ van, Anema J, Schirm J, Tegzess AM, The TH (1988) Rapid immunodiagnosis of active cytomegalovirus infection by monoclonal antibody staining of blood leukocytes. *J Med Virol* 25: 179–188
4. Billingham ME (1987) Cardiac transplant atherosclerosis. *Transplant Proc* 19: 19–25
5. Billingham ME, Nathaniel RB, Cary MRCP, Hammond ME, Kemnitz J, Marboe C, McCallister HA, Snovar DC, Winters GL, Zerbe A (1990) A working formulation of the standardization of nomenclature in the diagnosis of heart and lung rejection: heart rejection study group. *J Heart Transplant* 9: 587–593
6. Dummer JS, White LT, Ho M, Griffith BP, Hardesty RL, Bahnson HT (1985) Morbidity of cytomegalovirus infection in recipients of heart or heart-lung transplants who received cyclosporine. *J Infect Dis* 152: 1182–1191
7. Everett JP, Hershberger RE, Norman DJ, Chou S, Ratkovec RM, Cobanogly A, Ott GY, Hosenpud JD (1992) Prolonged cytomegalovirus infection with viremia is associated with development of cardiac allograft vasculopathy. *J Heart Lung Transplant* 11: S 133–137
8. Fujinami RS, Nelson JA, Walker L, Oldstone MB (1988) Sequence homology and immunologic cross-reactivity of human cytomegalovirus with HLA-DR beta-chain: a means for graft rejection and immunosuppression. *J Virol* 62: 100–105
9. Gao SZ, Alderman EL, Schroeder JS, Silverman JF, Hunt SA (1988) Accelerated coronary vascular disease in the heart transplant patient: coronary arteriographic findings. *J Am Coll Cardiol* 12: 334–340
10. Grattan MT, Moreno-Cabral CE, Starnes VA, Oyer PE, Stinson EB, Shumway NE (1989) Cytomegalovirus infection is associated with cardiac allograft rejection and atherosclerosis. *JAMA* 261: 3561–3566
11. Hayflick L (1989) Antecedents of cell aging research. *Exp Gerontol* 24: 355–365
12. Hendrix MGR, Dormans PHJ, Kitslaar P, Bosman F, Bruggeman CA (1989) The presence of cytomegalovirus nucleic acids in arterial walls of atherosclerotic and nonatherosclerotic patients. *Am J Pathol* 134: 1151–1157
13. Hosenpud JD, Shipley GD, Wagner CR (1992) Cardiac allograft vasculopathy: current concepts, recent developments and future directions. *J Heart Lung Transplant* 11: 9–23
14. Hruban RH, Wu TC, Beschoner WE, Cameron DE, Ambinder RF, Baumgartner WA, Reitz BA, Hutchins GM (1990) Cytomegalovirus nucleic acids in allografted hearts. *Hum Pathol* 21: 981–988
15. Johnson DE, Alderman EL, Schroeder JS, Gao SZ, Hunt S, DeCampi WM, Stinson E, Billingham M (1991) Transplant coronary artery disease: histopathologic correlations with angiographic morphology. *J Am Coll Cardiol* 17: 449–457

16. Loebe M, Schueler S, Zais O, Warnecke H, Fleck E, Hetzer R (1990) Role of cytomegalovirus infection in the development of coronary artery disease in the transplanted heart. *J Heart Transplant* 9: 707–711
17. McDonald K, Rector TS, Braunlin EA, Kubo SH, Olivari MT (1989) Association of coronary artery disease in cardiac transplant recipients with cytomegalovirus infection. *Am J Cardiol* 64: 359–362
18. Olivari MT, Homans DC, Wilson RF, Kubo SH, Ring WS (1989) Coronary artery disease in cardiac transplant patients receiving triple-drug immunosuppressive therapy. *Circulation* 80 [Suppl 3]: 111–115
19. Ross R, Wight T, Strandness E, Thiele E (1984) Human atherosclerosis I. Cell constitution and characteristics of advanced lesions of the superficial femoral artery. *Am J Pathol* 114: 79–93
20. Scott CD, Colquhoun IW, Gould K, Au J, Dark JH (1992) Determinants of graft arteriosclerosis after heart transplantation. *Transpl Int* 5 [Suppl 1]: S 238–241
21. Weimar W, Balk AHMM, Metselaar HJ, Mochtar B, Rothbarth PH (1991) On the relation between cytomegalovirus infection and rejection after heart transplantation. *Transplantation* 52: 162–163
22. Willebrand E von, Pettersson E, Ahonen J, Häyry P (1986) CMV infection, class II antigen expression, and human kidney allograft rejection. *Transplantation* 42: 364–367